CODE: T0800 M9693/1

ID NOS: H63321 91179

DIAGNOSIS: LYMPH NODE - FOLLICULAR LYMPHOMA

CLINICAL HISTORY: M. This specimen came from a man in whom a swelling had been present in the submandibular region for two months.

MACROSCOPIC: On the left, the pale buff coloured lobulated tissue is typical of a salivary gland. To the right is an enlarged lymph node, the cut surface of which is pale and shows no identifiable architectural structure.
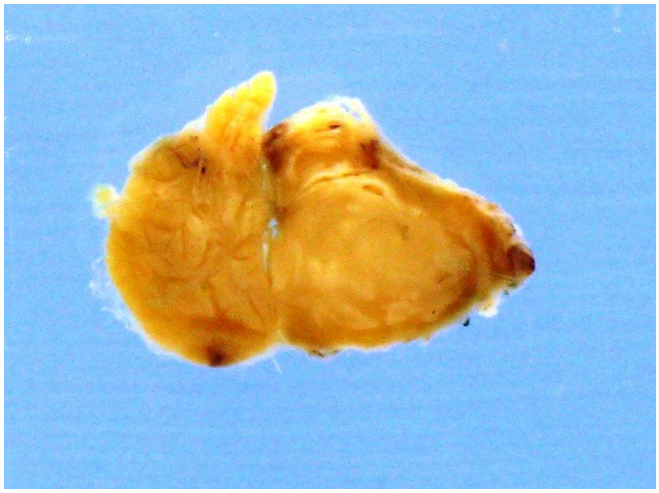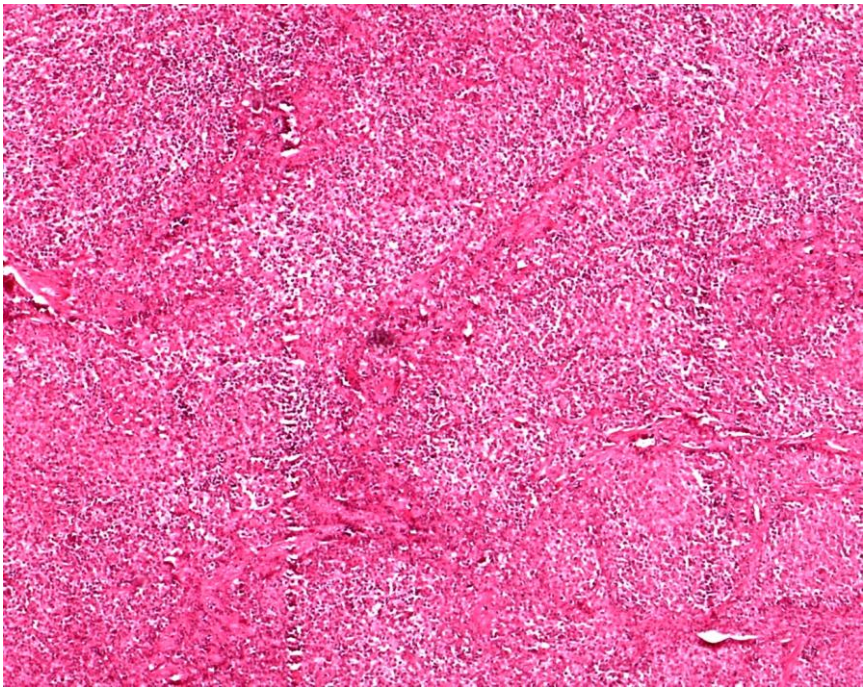
MICROSCOPIC: Large distorted pale follicles have replaced the normal architecture; no germinal centres are to be seen.