CODE: TX111 M9533/1

ID NOS: HX95672 A15306

DIAGNOSIS: MALIGNANT (ANAPLASTIC) MENINGIOMA – WHO GRADE III

CLINICAL HISTORY: M/75. Six months before death, a parasagittal malignant meningioma had been excised. The patient was readmitted five months later for removal of an infected craniotomy bone flap and drainage of pus. One week before death he developed left hemiparesis. Death resulted from both bronchopneumonia and myocardial infarction.

MACROSCOPIC: A mass of partly necrotic malignant tissue (60mm diameter) is adherent to the overlying dura and extends downwards displacing the subadjacent cerebrum. To the right can be seen an abscess, containing greenish pus, which has flattened the underlying cerebral ventricle.
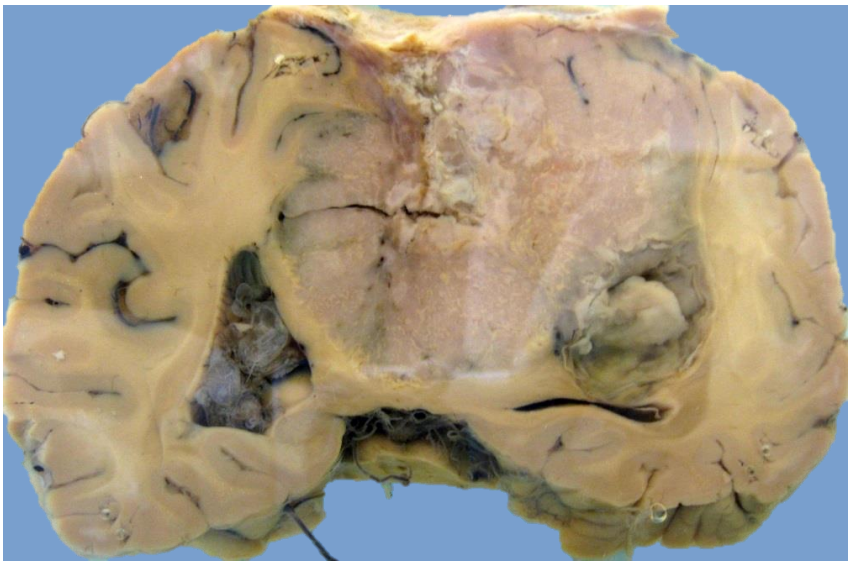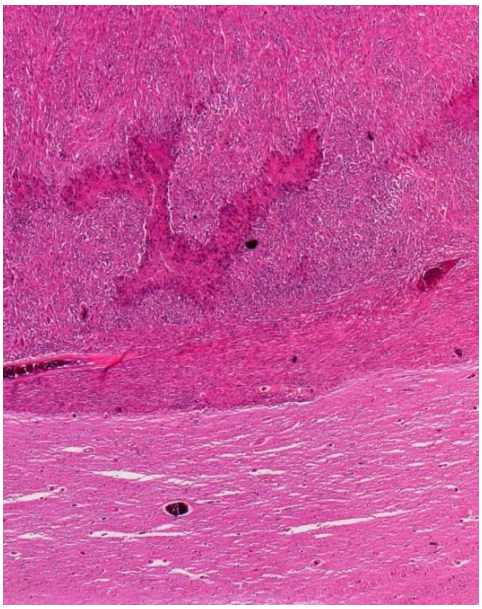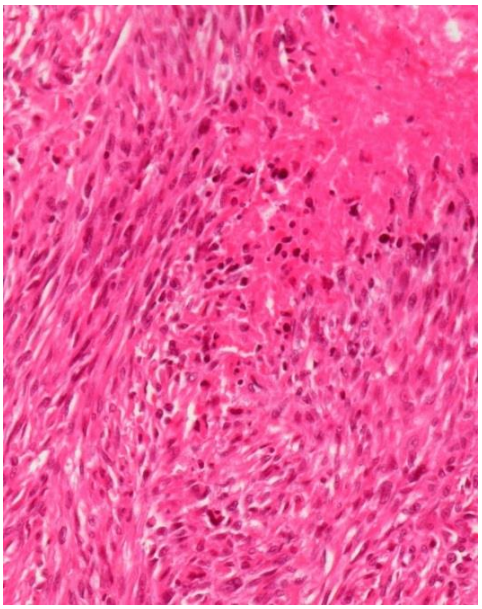
MICROSCOPIC: The left image shows the tumour with adjacent brain tissue below. The right image shows fascicles of pleomorphic mainly spindle-shaped tumour cells. Tumour necrosis is present at the upper right corner. .