CODE: TX200 M4174/1

ID NOS: HX10725 A15266

DIAGNOSIS: CEREBRAL ABSCESS (NOCARDIA ASTEROIDES)

CLINICAL HISTORY: M/56. The patient had received vigorous chemotherapy for Hodgkin's disease for nine months when twitching about the mouth appeared and subsequently Jacksonian fits developed. A CAT scan revealed lesions in the parietal region but brain needling did not lead to a diagnosis although an abscess or tumour suspected.

MACROSCOPIC: On both sides of this coronal section can be seen several large abscesses some of which still contain bright green pus and are bordered by a thin congested zone. Rupture had occurred to the ventricular system which was also filled with pus.
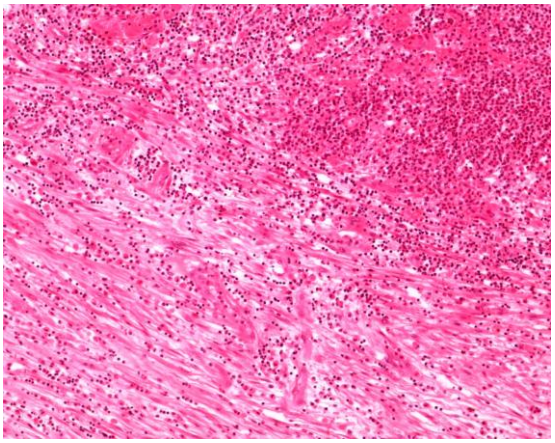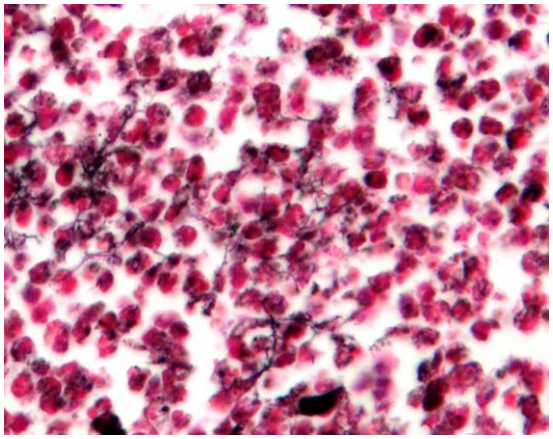
MICROSCOPIC: The abscess is filled with polymorphs whilst active organisation is progressing at the periphery. Methenamine silver stain demonstrated small colonies made up of slender, beaded, branching filaments typical of Nocardia.