CODE: TX200 M8006/4

ID NOS: HX1113205 A13931

DIAGNOSIS: BRAIN – METASTASES FROM CARCINOMA OF LUNG

CLINICAL HISTORY: M/60. Following a small haemoptysis, a chest Xray showed an opacity in the left hilum. A mediastinal biopsy showed poorly differentiated squamous carcinoma. Cobalt therapy was instituted but death occurred 12 months later preceded by behavioural disturbances. There was a history of heavy smoking for many years. Autopsy showed widespread metastases.

MACROSCOPIC: Mainly necrotic, partly cystic circumscribed lesions are revealed in this coronal section.
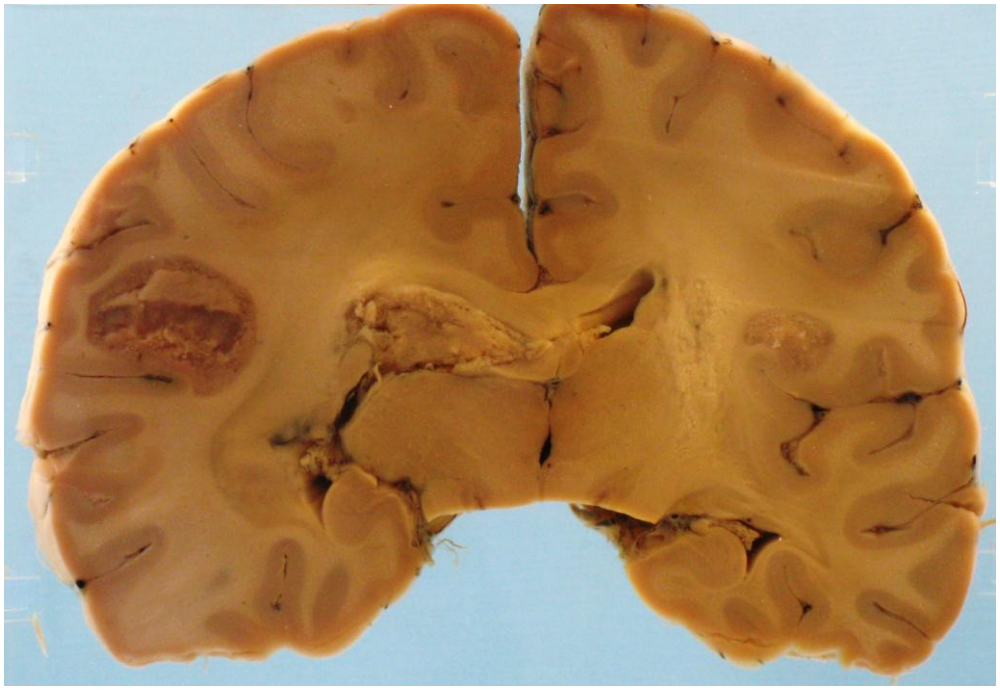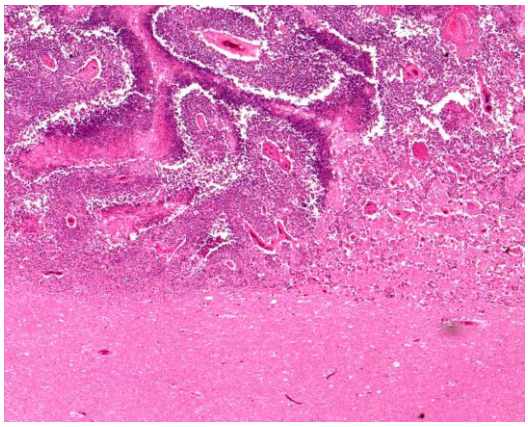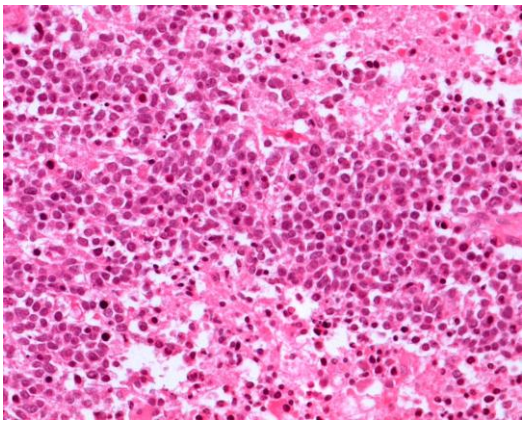
MICROSCOPIC: Undifferentiated carcinoma cells invade the cerebral cortex. There are areas of necrosis in the tumour.