CODE: TX200 M8006/6

ID NOS: HX161 A14842

DIAGNOSIS: CEREBELLUM – METASTATIC ADENOCARCINOMA OF CARDIO-OESOPHAGEAL JUNCTION

CLINICAL HISTORY: M/65. Cardio-oesophagectomy was performed for adenocarcinoma in that region. The neoplasm recurred at the site of anastomosis and death resulted from widespread metastases 8 months after the original operation. There were no symptoms to suggest the presence of intracranial metastases.

MACROSCOPIC: Section of the left cerebellar lobe shows a well delineated gelatinous neoplasm in which the blood vessels are particularly obvious.
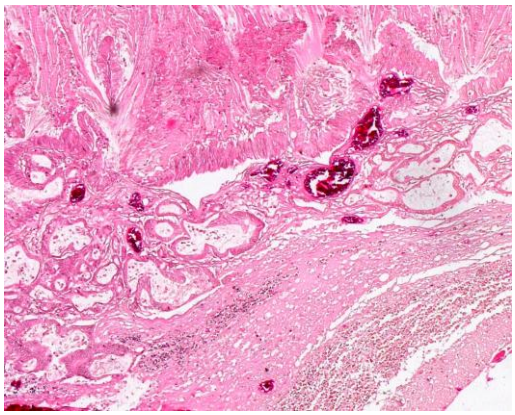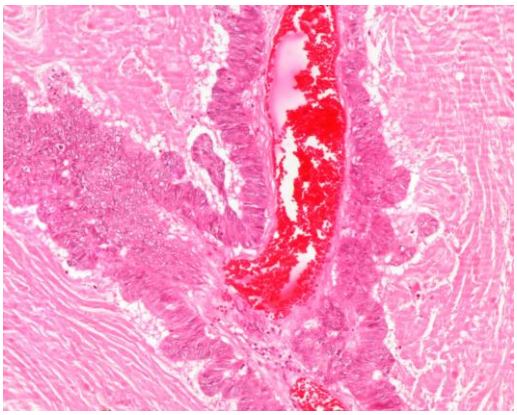
MICROSCOPIC: The left image shows the deposit of adenocarcinoma, with cerebellar tissue at the bottom right side. The right image shows malignant glandular epithelium surrounding s blood vessels. A considerable accumulation of mucus explains the macroscopic gelatinous appearance.