CODE: TX200 M9443/5

ID NOS: HX114319 A8175

DIAGNOSIS: BRAIN - GLIOBLASTOMA MULTIFORME (GRADE IV)

CLINICAL HISTORY: M/60. This patient complained of persistent headaches for six months. His demise followed rapidly increasing stupor and terminal coma.

MACROSCOPIC: The coronal section reveals the presence of a variegated poorly delineated tumour deep in the left tempo-parietal region. The superficial gyri are flattened and the lateral ventricles displaced well over to the left.
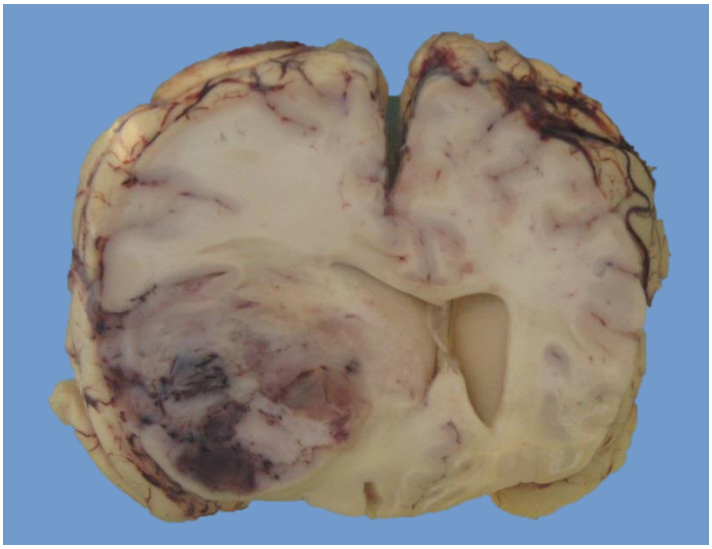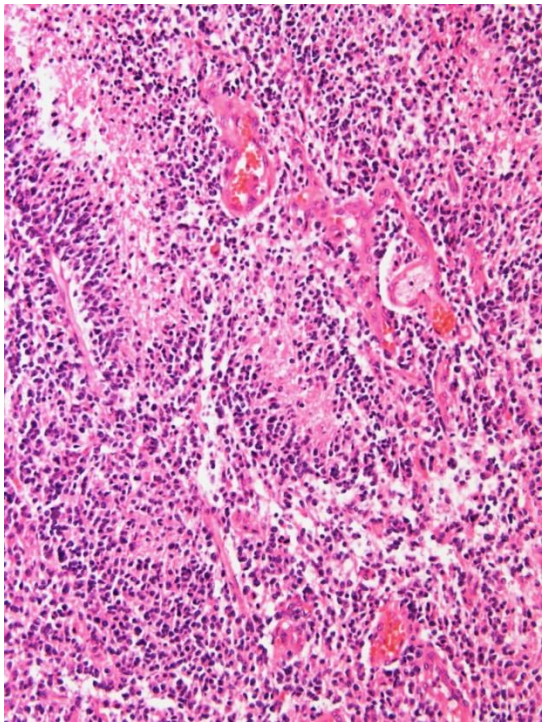
MICROSCOPIC: The tumour infiltrates into the surrounding cerebral tissue (left image). The tumour cells are poorly differentiated and show pseudopalisading of the nuclei, with necrosis and prominent vascular proliferation (right image).