CODE: T2410 M8073/3

ID NOS: HX25249 71717

DIAGNOSIS: PYRIFORM FOSSA - SQUAMOUS CELL CARCINOMA

CLINICAL HISTORY: M/70. The patient had a history of increasing dysphagia for about two weeks, especially with solid food. There had also been some haemoptysis. Laryngectomy was performed for carcinoma. At autopsy two months later, metastases were widespread.

MACROSCOPIC: The specimen consists of the right half of a larynx. Ulcerating carcinoma can be seen involving the inferior portion of the anterior aspect of the larynx. A neoplastic mass is also present posteriorly between the larynx and the anterior aspect of the oesophagus.
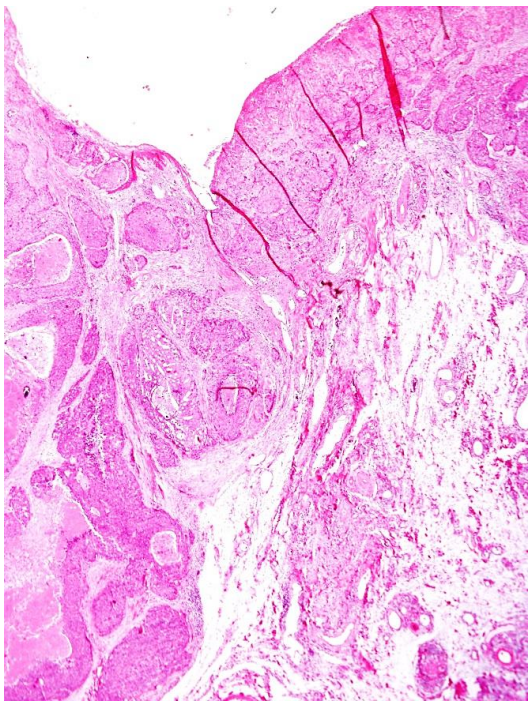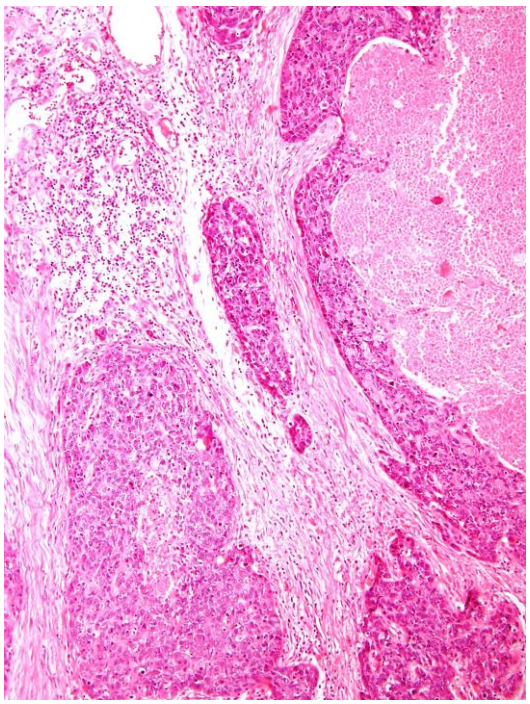
MICROSCOPIC: The tumour is a poorly differentiated squamous cell carcinoma with in situ carcinoma in the adjacent mucosa (left image). There is tumour necrosis and an associated inflammatory cell infiltrate (right image).