CODE: T2410 M8073/4

ID NOS: 217

DIAGNOSIS: LARYNX - SQUAMOUS CELL CARCINOMA

CLINICAL HISTORY: M/74. Laryngectomy was performed for biopsy proven squamous cell carcinoma

MACROSCOPIC: The specimen of the larynx shows an exophytic tumour on the left posterior wall above the level of the vocal cords.
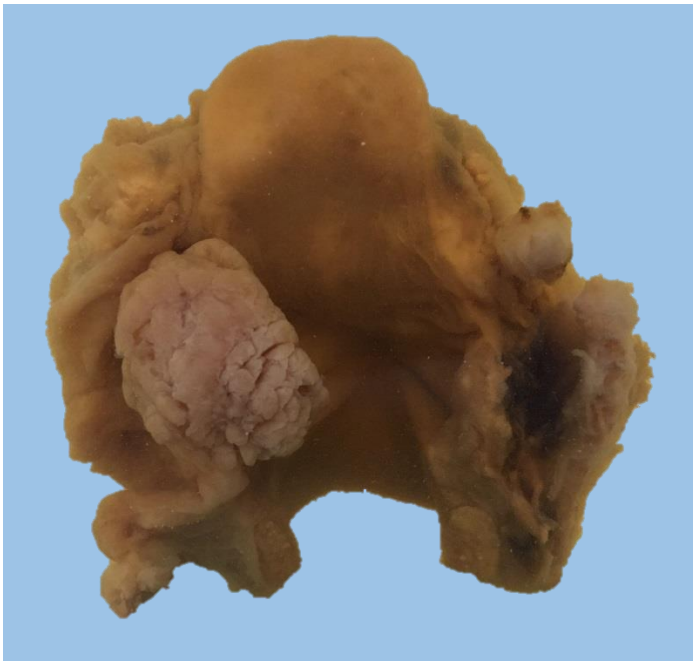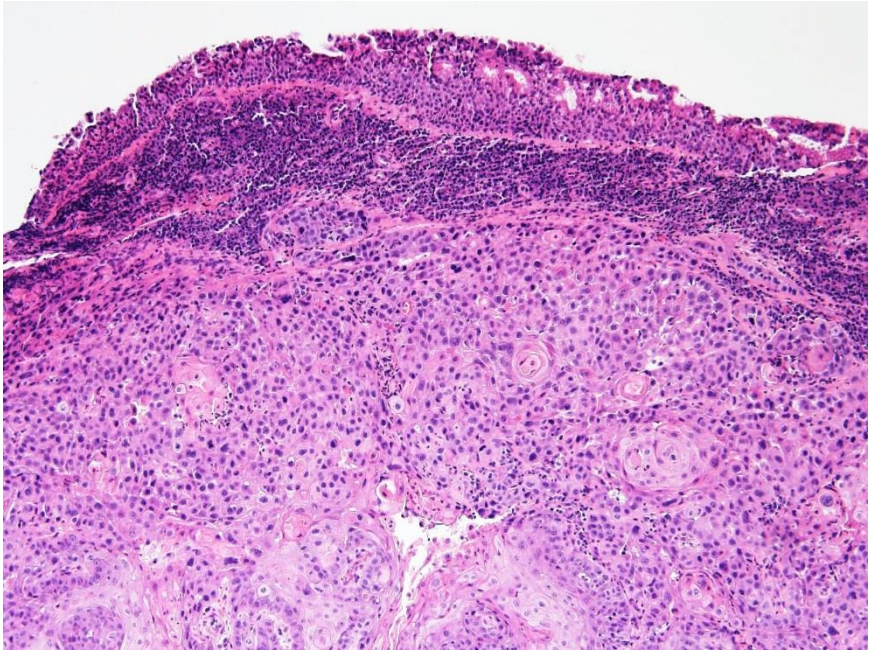
MICROSCOPIC: The tumour is an infiltrating squamous cell carcinoma with severe dysplasia of the overlying epithelium. There is also an associated inflammatory cell infiltration.