CODE: T2800 E1760/1

ID NOS: HX218603 A15530

DIAGNOSIS: LUNG - ATYPICAL MYCOBACTERIAL INFECTION

CLINICAL HISTORY: M/70. There was a ten year history of "chronic chest infection". Acid-fast bacilli were isolated and eventually identified as atypical mycobacteria Group 3 (Runyon). In spite of anti-tuberculosis therapy, dyspnoea gradually increased leading eventually to his demise.

MACROSCOPIC: This section shows the lung to be almost completely airless, the alveoli being apparently filled by partly pale and partly brownish exudate. The hilar nodes are enlarged and their peripheral sinuses pale and exaggerated.
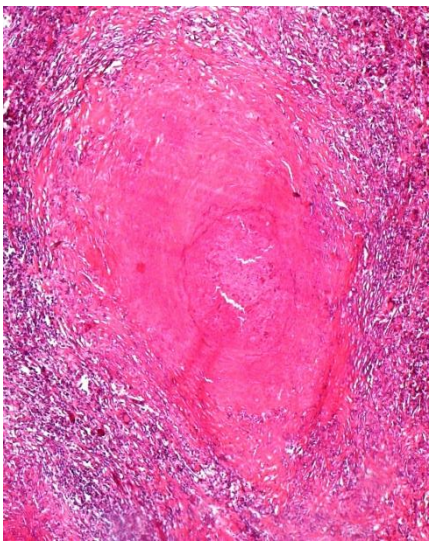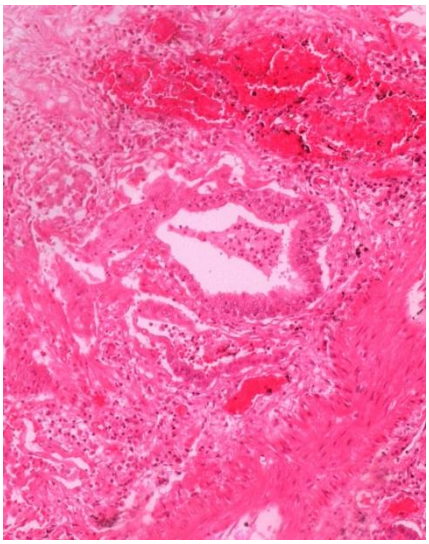
MICROSCOPIC: Caseating granulomas with an occasional giant cell are seen (left image). The remaining pulmonary tissue is fibrotic with striking epithelialisation of the remaining alveoli (eight image).