CODE: T2800 E4671

ID NOS: HKM1190 133128

DIAGNOSIS: LUNG – PULMONARY DIROFILARIASIS

CLINICAL HISTORY: M/55. The patient presented with vague chest pains and a history of chronic airways limitation. Chest Xray showed a "coin" lesion in the left lower lobe which was removed by wedge resection.

MACROSCOPIC: The specimen consists of a piece of thickened white fibrous pleura to which is attached a portion of lung tissue. This contains a bisected creamy grey nodule.

MICROSCOPIC: The nodule consist of infarcted tissue showing coagulative necrosis surrounded by a fibrous and granulomatous inflammatory reaction (a,b). A thrombosed blood vessel contains a thick walled structure with internal features indicating Dirofilaria worm (c,d) surrounded by a giant cell granulomatous reaction.

COMMENT: Dirofilaria imitis is the common heartworm of dogs. Man may be accidently infected by mosquito bites.

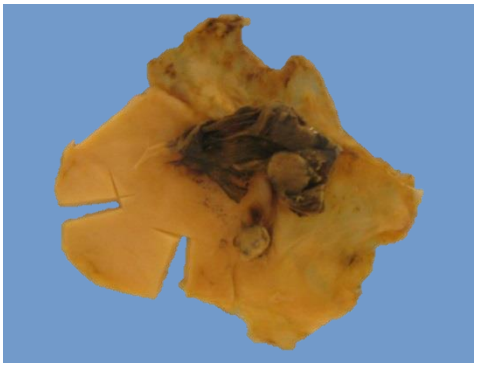

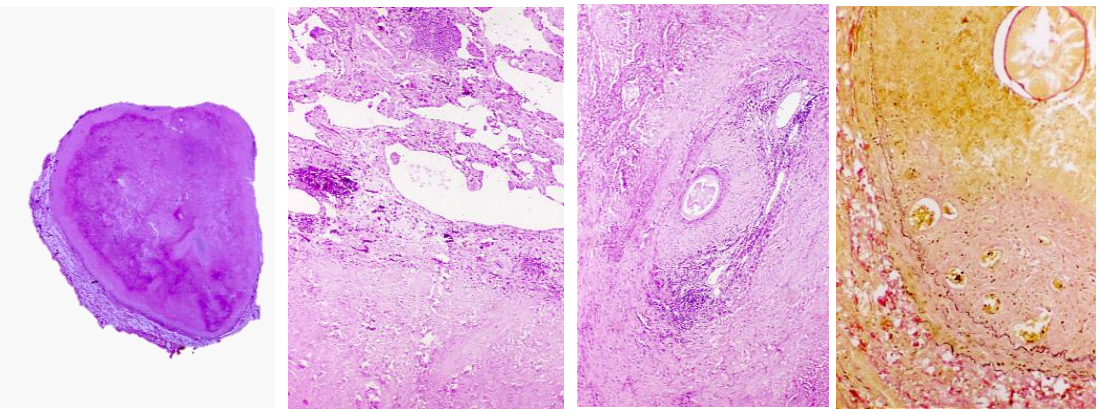
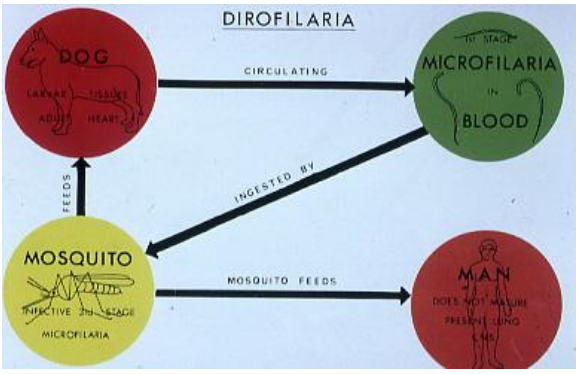
(a) (b) (c) (d) Elastic stain