**CODE:** T2800 F9339/1

**ID NOS:** 12394

**DIAGNOSIS:** LUNG - CRYPTOCOCCOCIS

**CLINICAL HISTORY:** M/39. Right upper lobectomy was performed for what was thought to be tuberculosis. No other history available.

**MACROSCOPIC:** Two slices of the lobe show that most of the lung substance is grey, gelatinous, and airless. It felt very firm and rubbery. The pale subpleural foci are areas of necrosis.
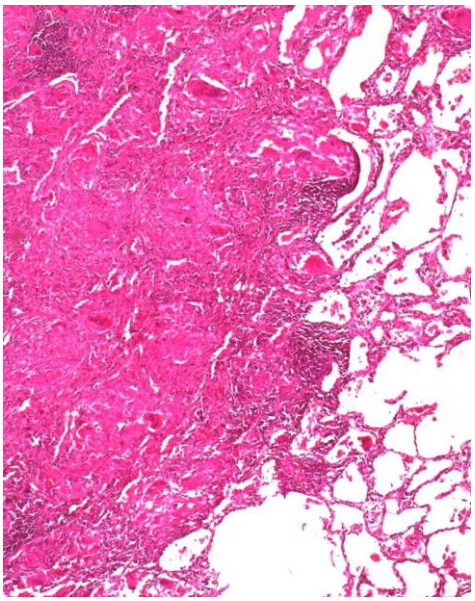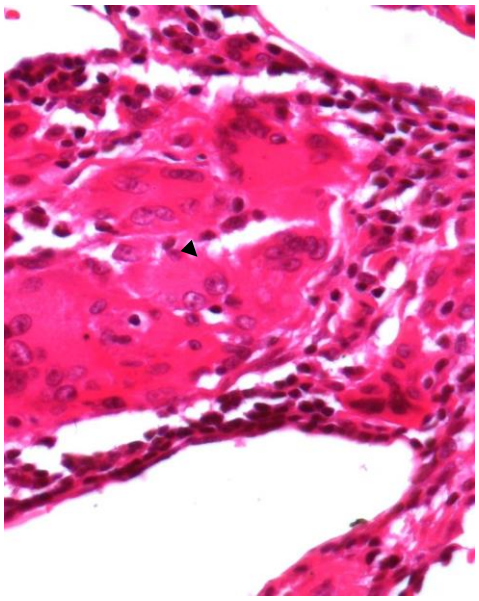
**MICROSCOPIC:** Most of the lung parenchyma is destroyed and replaced by a chronic granulomatous process (left image). A striking feature is the presence of large foreign body type giant cells; many of which are coarsely vacuolated. In some of these vacuoles there can be seen the typical yeast-like bodies of *Cryptococcus* (right image).