CODE: T2800 F9339/4

ID NOS: HCIV6142 70754

DIAGNOSIS: LUNG – CRYPTOCOCCOSIS (TORULOMA)

CLINICAL HISTORY: F/33. A coin lesion was seen in a routine chest X-ray. It was quite symptomless. However a Cryptococcus neoformans complement fixation test was strongly positive with a titre of 1:256. Right lower lobectomy was performed and recovery was uneventful, apart from a transient pneumothorax.

MACROSCOPIC: In the centre of this portion of resected lung is a clearly demarcated pale opaque lesion. Many torulomas have a rather more characteristic semi-translucent gelatinous appearance, but in this specimen it is not possible to make a definitive macroscopic diagnosis.
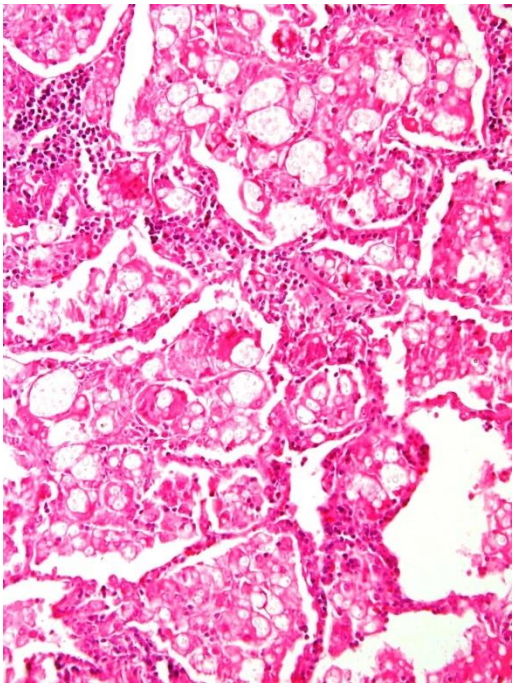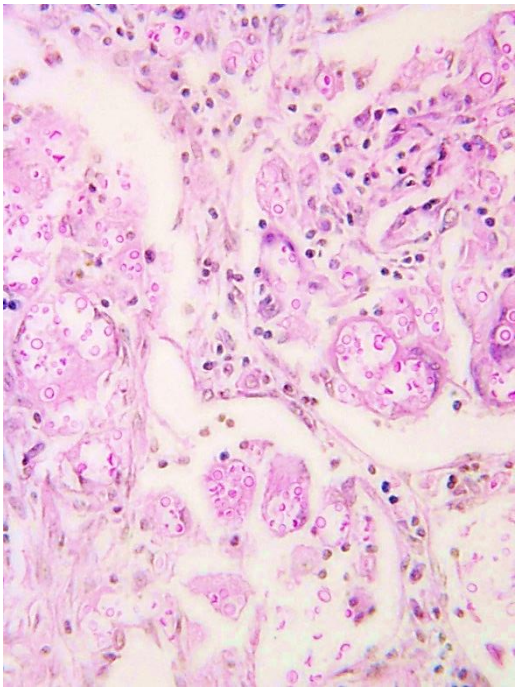
MICROSCOPIC: The alveolar spaces contain many round, refractile, unstained Cryptococcal organisms and there is a scattered infiltrate of chronic inflammatory cells (left image). The organisms are stained pink with a Mucicarmine stain (right image).