CODE: T2800 F9339/5

ID NOS: H322776 88019

DIAGNOSIS: LUNG - CRYPTOCOCCOSIS.

CLINICAL HISTORY: M/57. There was a history of cough for nine months and repeated small haemoptyses for three months. A radiological opacity was found towards the right apex which was thought to be due to carcinoma, but Cryptococcus was later isolated. Lobectomy was performed because the lesion did not resolve under specific therapy.

MACROSCOPIC: A yellowish well demarcated lesion occupies the apical portion of the lobe. The deeper parts are semitranslucent.
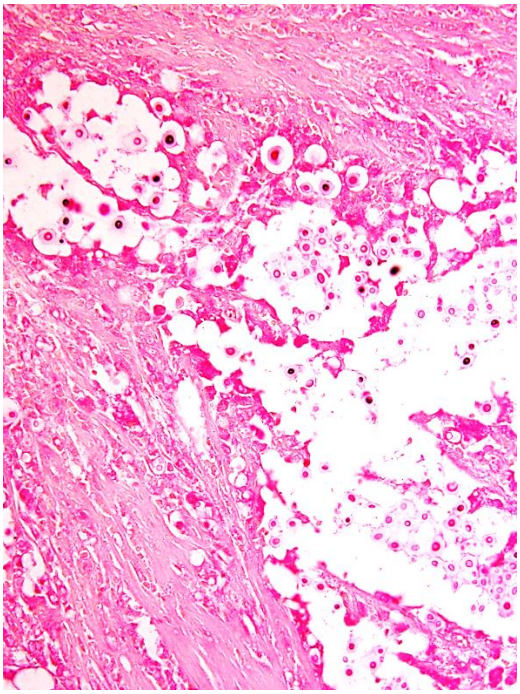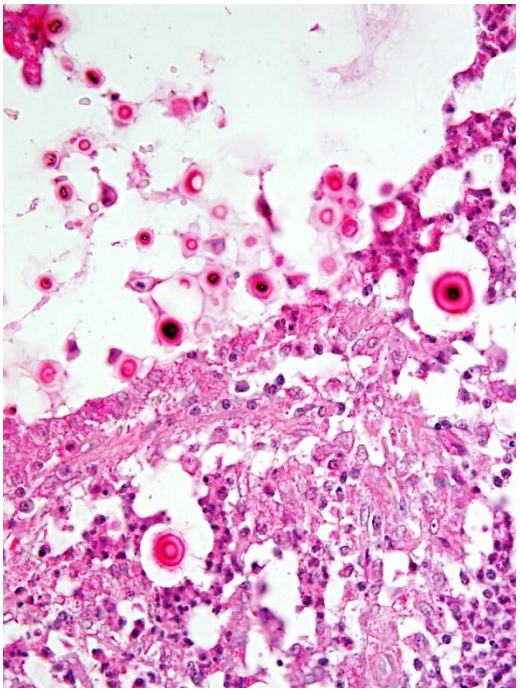
MICROSCOPIC: Large colonies of round yeast like organisms are broken up by bands of fibrous tissue (left image). The Cryptococci have a gelatinous capsule (right image).