CODE: T2800 F9494/20

ID NOS: H34929 A6211

DIAGNOSIS: LUNG - ACUTE CASEOUS PNEUMONIA WITH MILLIARY SPREAD

CLINICAL HISTORY: M/67. Admission to hospital followed a six month history of increasing tiredness and pallor. There was consolidation of the apices of both lungs. Acute leukaemia and pulmonary tuberculosis were diagnosed; death ensuing some ten days later.

MACROSCOPIC: There is pale consolidation of most of the upper lobe with areas of lighter coloured caseation. In the lower lobe there are scattered pale foci throughout and their even distribution suggests a haematogenous spread. Miliary tubercles were also found in the liver and spleen.
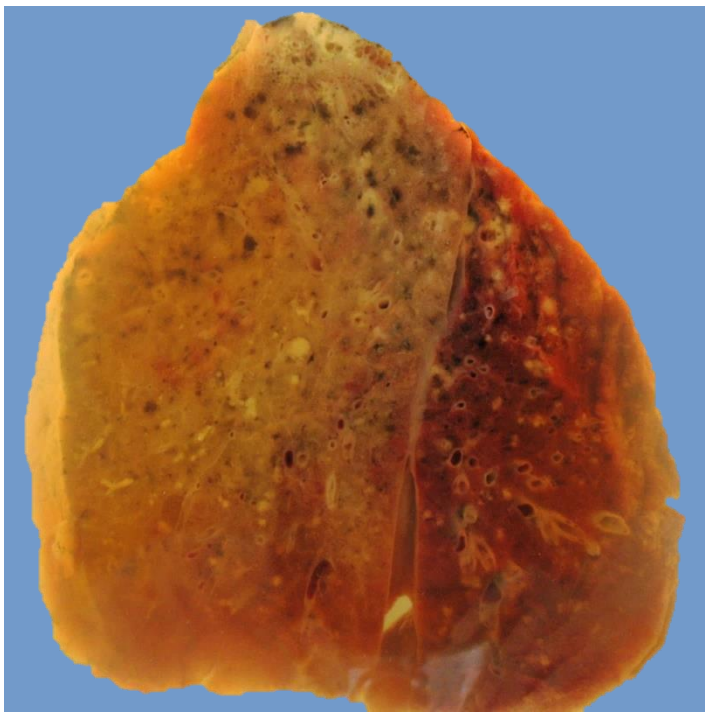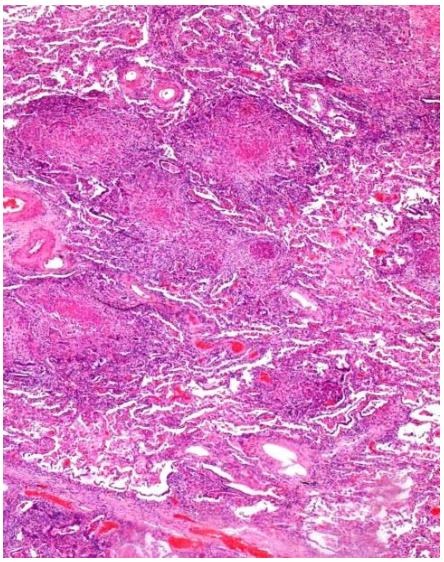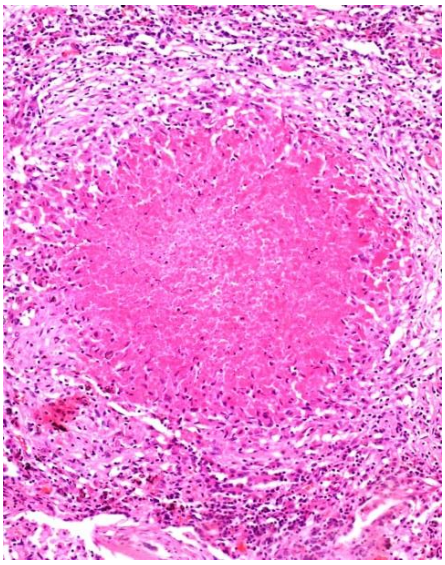
MICROSCOPIC: Multiple caseating granulomas are present. Rapid caseation in the absence of giant cells indicate the acuteness of the condition.