CODE: T2800 F9494/3

ID NOS: 6136

DIAGNOSIS: FIBROCASEOUS TUBERCULOSIS

CLINICAL HISTORY: M/48. A right upper lobectomy was performed following the radiological finding of a “cavity with sclerosed walls”.

MACROSCOPIC: Just below the apex of the upper lobe there is a pale caseous lesion which has undergone partial cavitation.
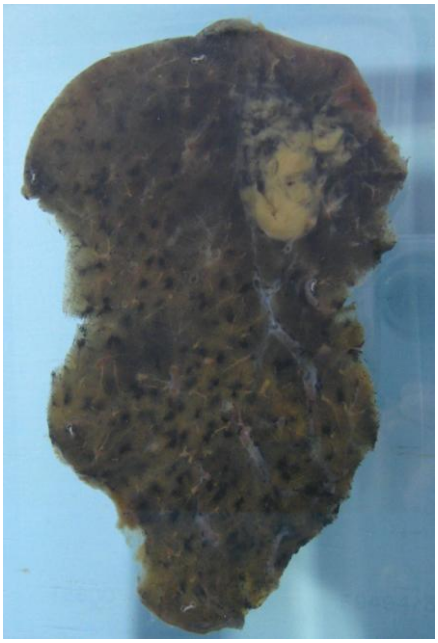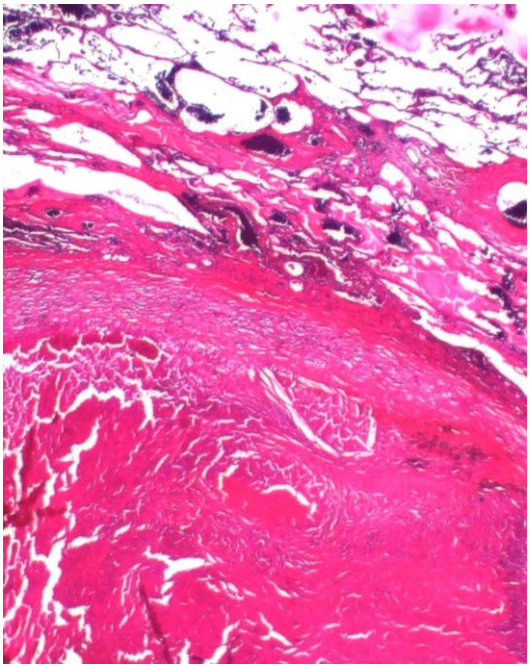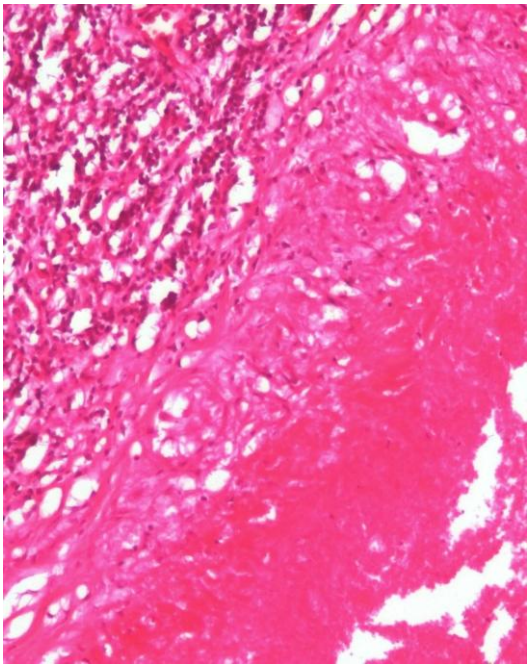
MICROSCOPIC: The area of pink staining caseous necrosis is surrounded by a layer of pale epithelioid macrophages, fibrous tissue, and aggregations of small round cells – mainly lymphocytes. Acid-fast bacilli were demonstrated. Tubercles were present in the bronchial mucosa, but the hilar nodes were uninvolved.