CODE: T2800 F9494/5

ID NOS: 190067 5835

DIAGNOSIS: LUNG - FIBROCASEOUS TUBERCULOSIS

CLINICAL HISTORY: M/25. This young man presented with cough, blood stained sputum and loss of weight. A chest X-ray showed opacities in the right upper and middle lobes. Acid fast bacilli were found in his sputum. Thoracoplasty did not prevent extension of the disease, and lobectomy was performed 9 months later.

MACROSCOPIC: The cut surface of this lobe shows many pale areas of caseation, of which two of the largest have undergone cavitation. Pale fibrous tissue surrounds some of the lesions.
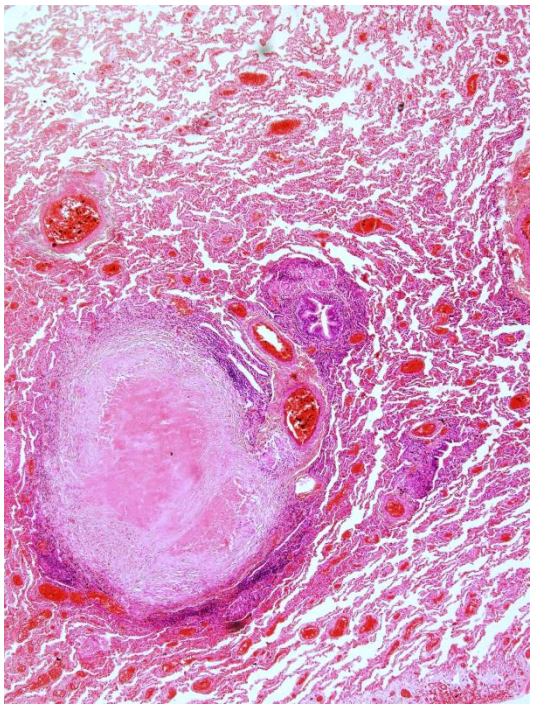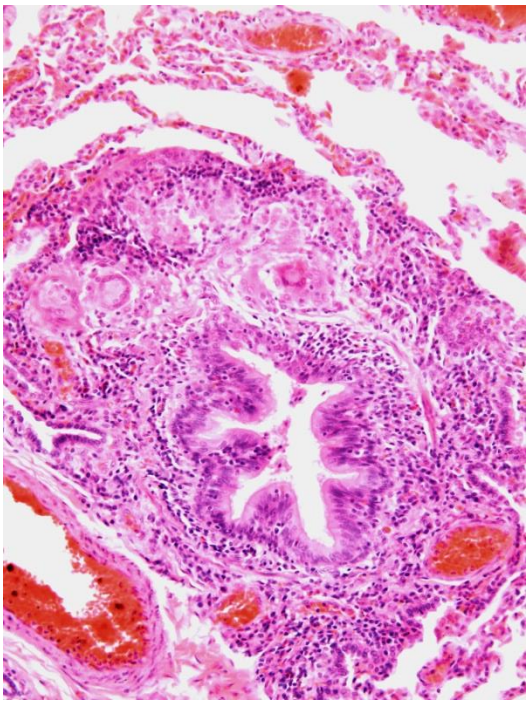
MICROSCOPIC: There is a pink staining nodule of caseation seen (left image). The presence of several small tubercles adjacent to a small bronchiole suggests the route of infection to surrounding lung tissue to be via peribronchial lymphatics (right image).