CODE: T2800 M0001

ID NOS: None

DIAGNOSIS: NORMAL LUNG.

CLINICAL HISTORY: The only available information is that the patient died of unrelated cause.

MACROCSOPIC: The specimen is a slice of the left lung with no obvious abnormality. On the reverse side of the specimen there are a few small hilar lymph nodes with carbon pigment.
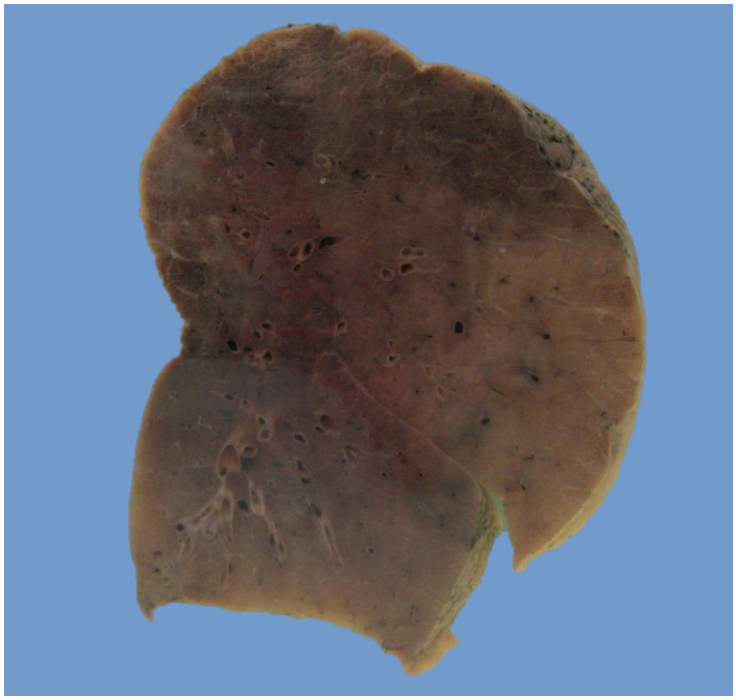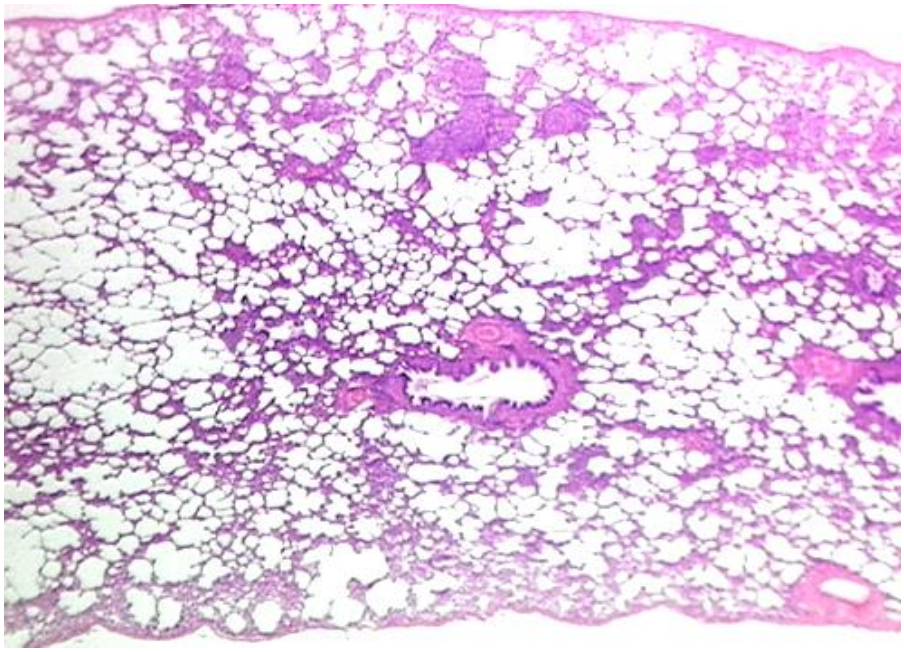
MICROSCOPIC: The image show a bronchiole which is lined by columnar epithelium. The terminal bronchioles are continuous with the alveolar ducts, from which the alveolar spaces arise.