CODE: T2800 M3412/2

ID NOS: 54737 8316

DIAGNOSIS: LUNG BRONCHIECTASIS.

CLINICAL HISTORY: The only surviving information is that radiographic investigation of the chest shows "saccular bronchiectasis of the left base". The lower lobe of the left lung was surgically removed.

MACROSCOPIC: The upper part of the lobe is congested but otherwise normal. In the lower portion, normal bronchi can be seen leading into a series of thin-walled sacs with a linear distribution. These represent the more distally distributed bronchi which have undergone dilatation. On the lateral aspect, the lung is collapsed and fibrotic.
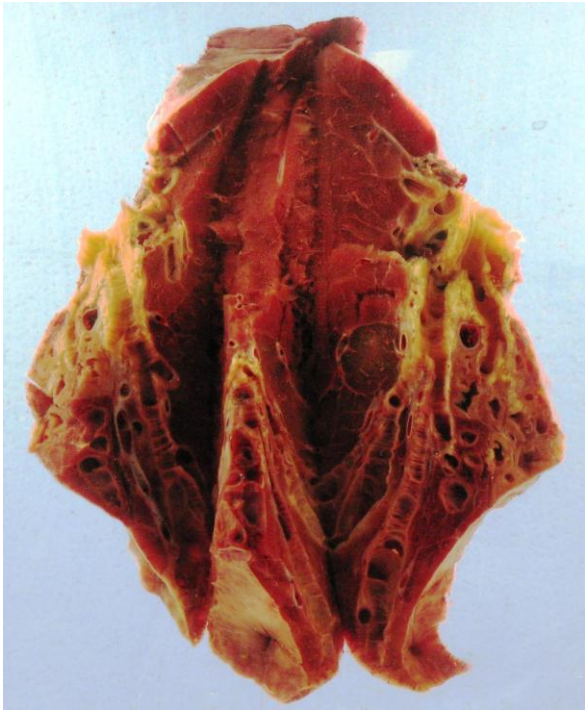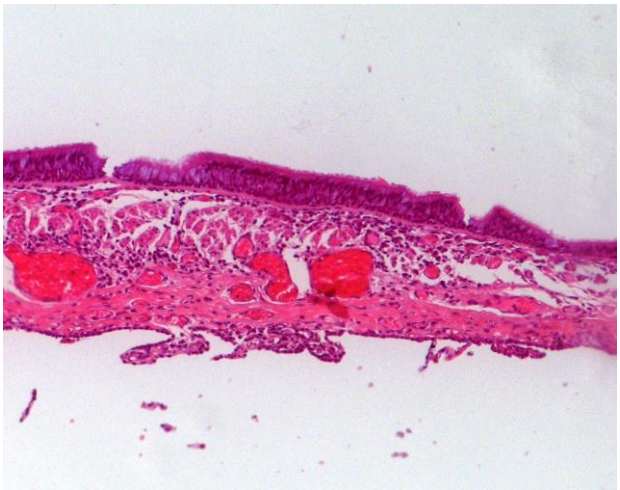
MICROSCOPIC: The margin of a thin-walled cavity is made up of attenuated bronchial wall in which remnants of smooth muscle are still recognisable.