**CODE:** T2800 M5603/1

**ID NOS:** H99689 A11333

**DIAGNOSIS:** LUNG - COAL WORKERS' PNEUMOCONIOSIS
PROGRESSIVE MASSIVE FIBROTIC TYPE

**CLINICAL HISTORY:** M/81. This man had been a coal miner for many years and had had radiological evidence of pneumoconiosis for at least four years. He died of cardiac failure with superimposed bronchopneumonia.

**MACROSCOPIC:** A large black scar with associated cavitation has destroyed most of the upper lobe. It typically involves the interlobar fissure. The other lung was similarly affected. The lower lobe shows the lesions of focal dust emphysema; the so-called 'simple' form of coal workers' pneumoconiosis.
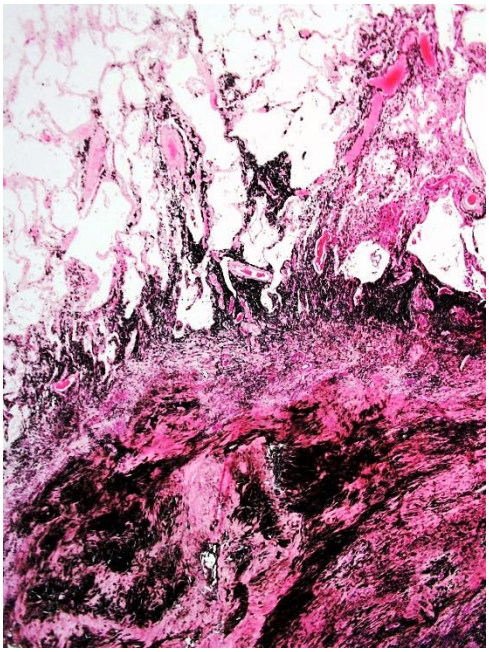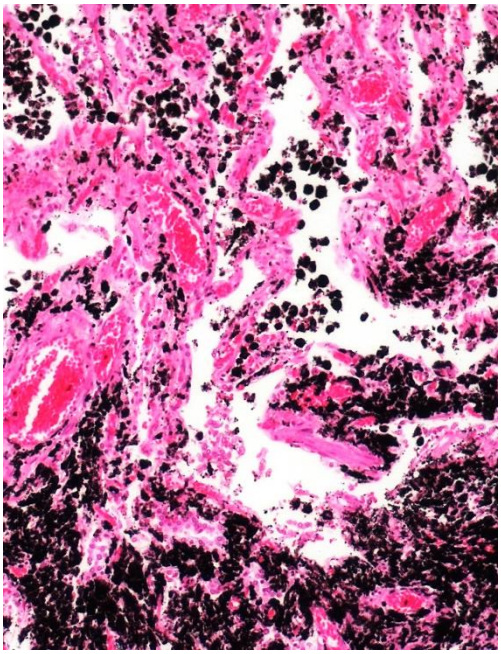
**MICROSCOPIC:** The left image shows the edge of a dense fibrous scar containing abundant carbon pigment, and extending into the adjacent lung parenchyma. Carbon pigment is present in macrophages within alveolar spaces (right image).