CODE: T2800 M8006/3

ID NOS: HX88891 A11188

DIAGNOSIS: LUNG – METASTATIC OSTEOSARCOMA.

CLINICAL HISTORY: M/60. About five years before death, amputation was performed for osteosarcoma of the lower part of the femoral shaft. At his final admission the patient complained of increasing cough and dyspnoea.

MACROSCOPIC: The cut surface of this lung shows massive pale lesions up to 8cm in diameter. Some of the surrounding lung is grey and airless. The other lung was similarly affected.
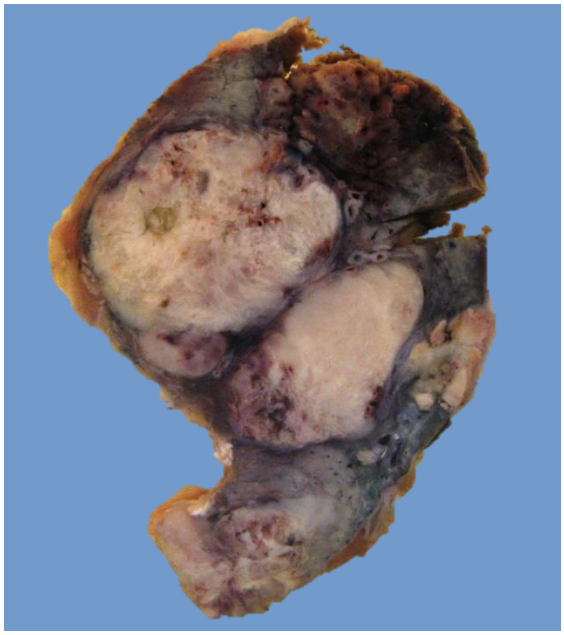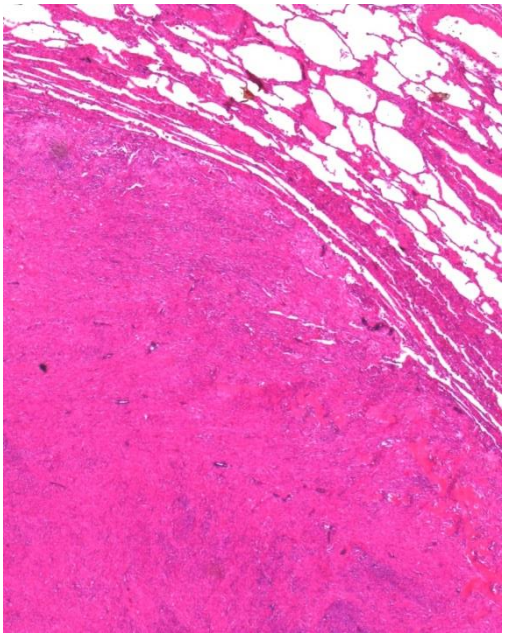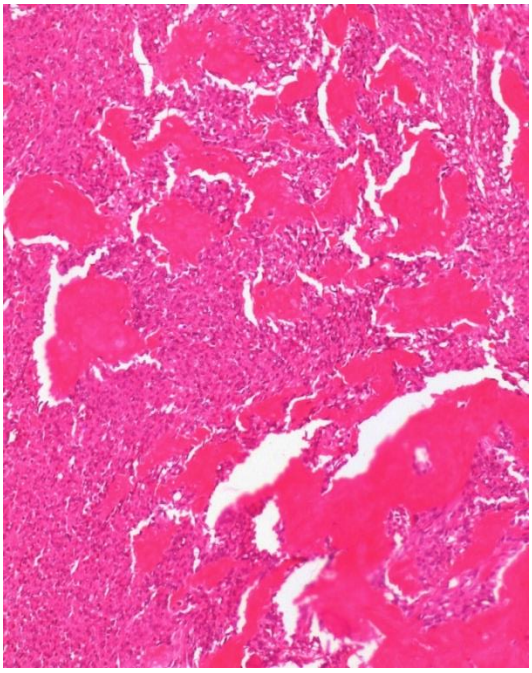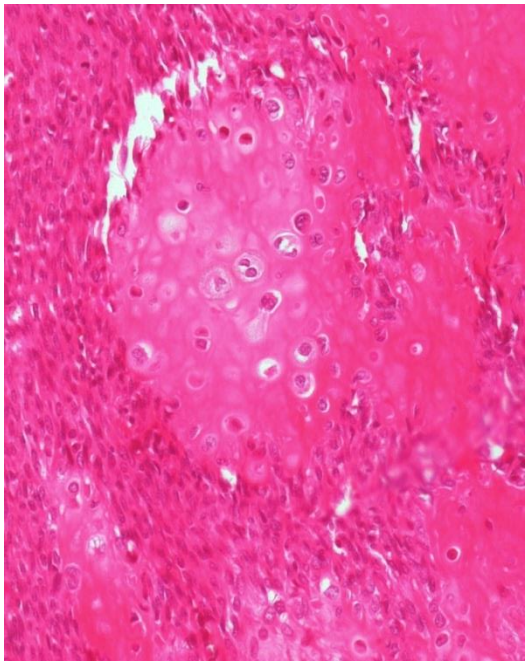
MICROSCOPIC: The tumours are well demarcated from the surrounding lung tissue, and mostly have a fibrosarcomatous pattern (upper right image). There are areas of osteoid (lower left image) and cartilage (lower right image).