CODE: T2800 M8013/10

ID NOS: HX94654 124010

DIAGNOSES: LUNG – LARGE CELL CARCINOMA

CLINICAL HISTORY: M/71. The patient was a heavy smoker. He presented with chronic cough and increasing dyspnoea for two months. Biopsy of a lesion in left upper lobe showed large cell undifferentiated carcinoma. Left upper lobectomy was performed.

MACROSCOPIC: The specimen consists of a portion of the upper lobe of the left lung, in which there is a moderately well-circumscribed solid white tumour extending from the bronchus to with 5mm of the pleural surface.
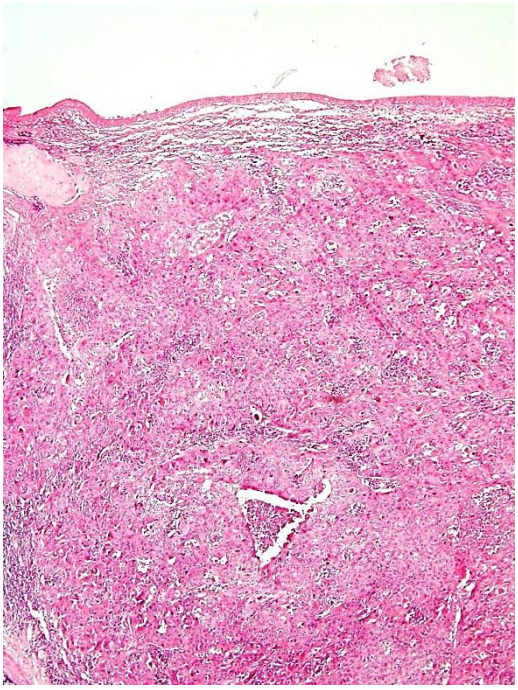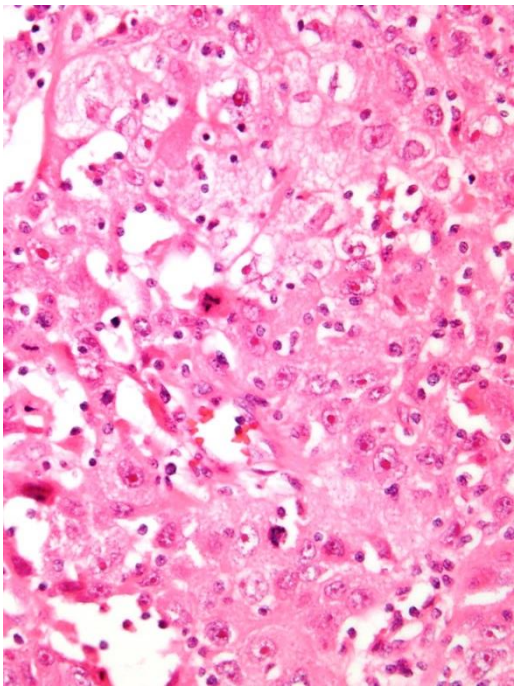
MICROSCOPIC: Sections show tumour cells infiltrating beneath the bronchial epithelium (left image). The large carcinoma cells are arranged in sheets and have prominent nucleoli with scattered abnormal mitoses (right image).