CODE: T2800 M8013/4

ID NOS: HX107185 A7654

DIAGNOSIS: LUNG - ADENOCARCINOMA.

CLINICAL HISTORY: M/51. When first admitted to hospital, this patient was thought to be suffering from a cerebral abscess. Subsequently chest Xray showed a rounded peripheral opacity in the left lung and the clinical diagnosis was changed to that of cerebral metastases from cancer of the lung.

MACROSCOPIC: The autopsy specimen shows a pale rounded neoplasm at the periphery of the left upper lobe. A small bronchus can be seen to lead into the lesion. Several cerebral metastases were demonstrated post mortem but none were found elsewhere.
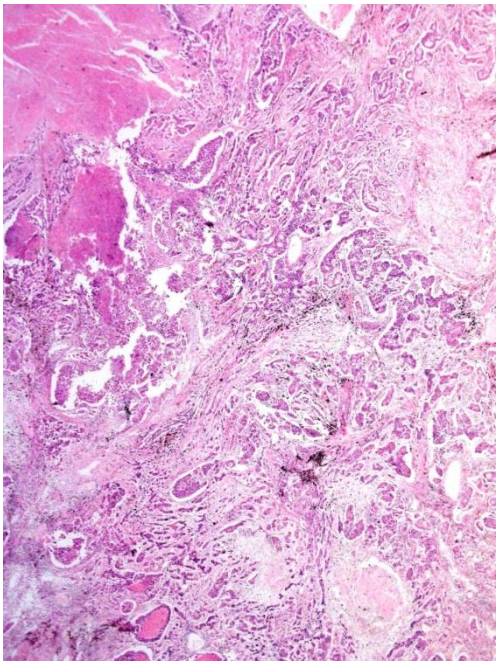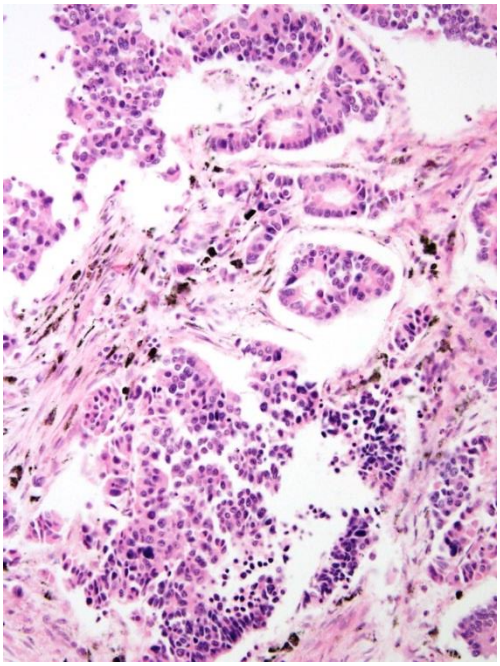
MICROSCOPIC: There are areas of pink staining tumour necrosis (left image). Much of the tumour is poorly differentiated, with some areas of gland formation present (right image).