CODE: T2800 M8013/5

ID NOS: HX17093 18903

DIAGNOSIS: LUNG - SQUAMOUS CARCINOMA

CLINICAL HISTORY: M/51. Pneumonectomy was performed for carcinoma.

MACROSCOPIC: The main bronchus to the upper lobe is occluded by pale neoplastic tissue. The upper portion of this lobe is collapsed, and its cut surface shows pale areas of suppuration. The marbled appearance of one hilar lymph node results from metastases; those nodes more medial are uninvolved.
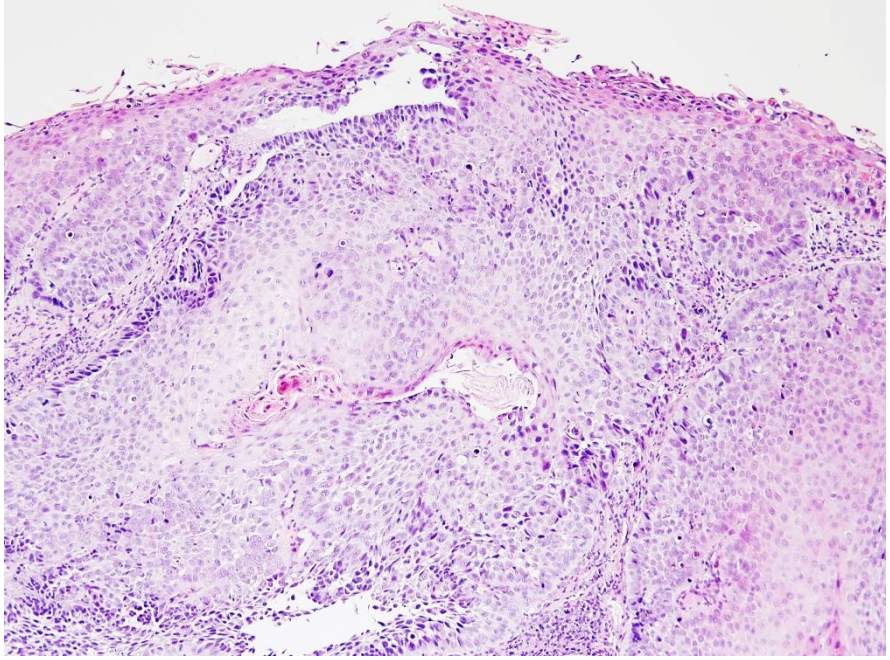
MICROSCOPIC: The bronchial mucosa has been mainly replaced by moderately differentiated squamous cell carcinoma.