CODE: T2800 M8013/6

ID NOS: NX133939 7956

DIAGNOSIS: LUNG - ADENOCARCINOMA

CLINICAL HISTORY: M/44. Right pneumonectomy was performed for carcinoma of the lung. No other clinical information is available.

MACROSCOPIC: There is a well-demarcated pale carcinoma near the hilum which was shown to involve the lower lobe bronchus and, to a lesser extent, that of the middle lobe. Some adipose tissue is adherent to the diaphragmatic surface. On the reverse the lower lobe is collapsed, the bronchi crowded, and the parenchyma destroyed by inflammatory processes.
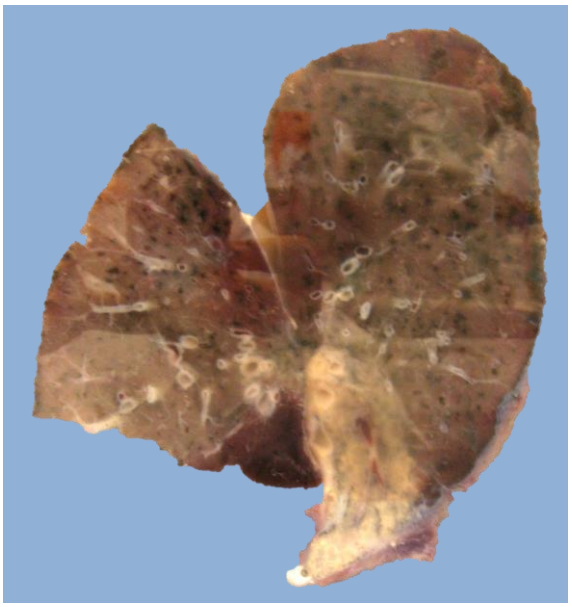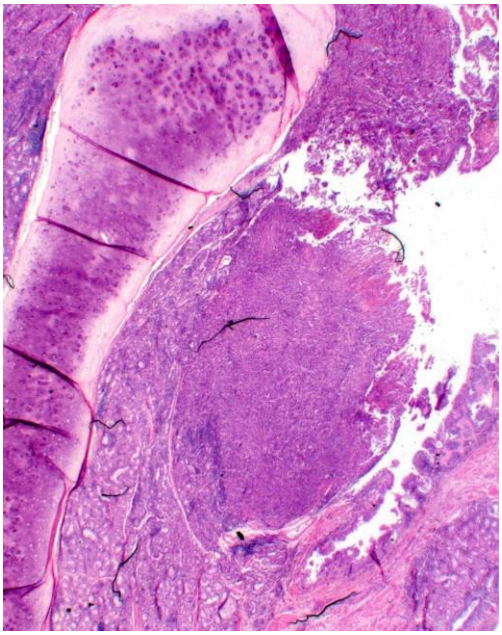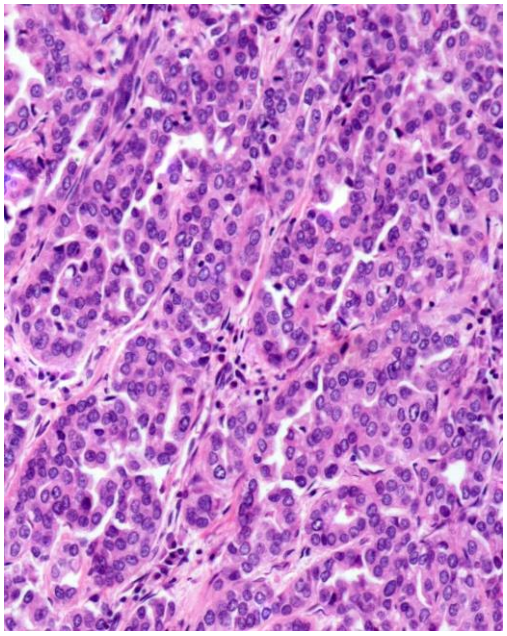
MICROSCOPIC: The tumour extends into the bronchus with the cartilage of the bronchial wall evident (left image). The tumour is a poorly-differentiated adenocarcinoma composed of large cells with some gland formation (right image).