CODE: T2800 M8013/8

ID NOS: HX104479 A14927

DIAGNOSIS: LUNG – SMALL CELL NEUROENDOCRINE CARCINOMA

.

CLINICAL HISTORY: M/57. This patient was a heavy cigarette smoker (50 a day) and was admitted to hospital complaining of recent and rapidly increasing shortness of breath. A blood stained pleural effusion was tapped and cancer cells were found in it. He died three weeks later.

MACROSCOPIC: This slice of lung shows the main bronchus to be surrounded by pale tan malignant tissue. This tissue extends into the hilum and downwards between lung and pericardium. Small metastases are present in a lymph node and the bronchial mucosa is congested and nodular. Patchy consolidation involves the more peripheral lung tissue. Metastases were also present in the brain and elsewhere.
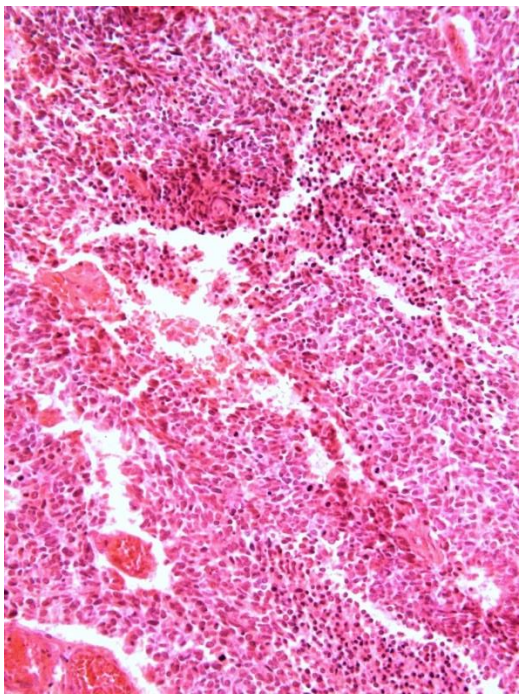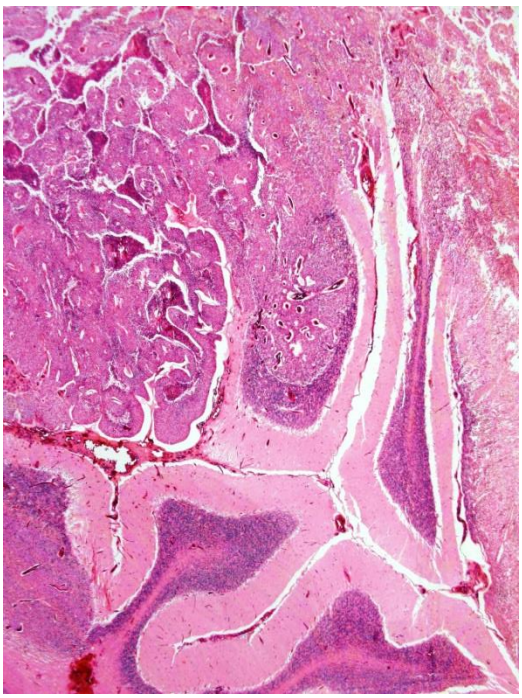
MICROSCOPIC: The malignant cells have only scanty cytoplasm and their nuclei are fusiform, and foci of necrosis are present (left image). Metastatic carcinoma is present in the cerebellum (right image).