CODE: T2800 M8013/9

ID NOS: H334875 A15308

DIAGNOSIS: LUNG – CARCINOMA WITH ABSCESS FORMATION

CLINICAL HISTORY: F/74. This patient complained of loss of weight, worsening cough and sputum. She had smoked at least 40 cigarettes per day. She was thought to have pneumonia of the right lower lobe, and died 3 days after admission to hospital.

MACROSCOPIC: The right lower lobe bronchus is obstructed by an encircling pale neoplasm, distal to which a large abscess has developed. The tumour has spread to involve the pleura on the medial aspect of the lower lobe in close relationship to the pericardium. (See specimen T3100 M4100/3). Metastatic deposits were present in the hilar nodes and the kidneys. One of the major pulmonary vessels is obstructed by tumour (see reverse) which has precipitated thrombosis.
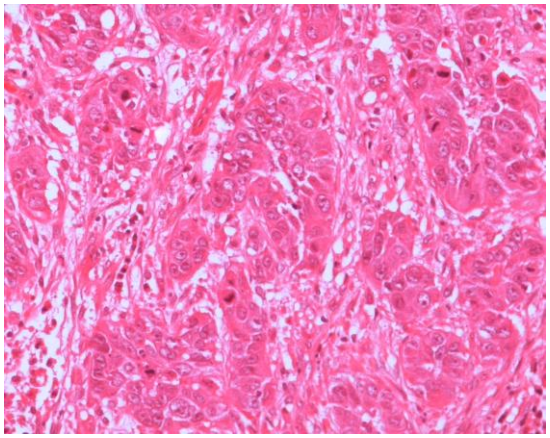
MICROSCOPIC: The tumour is a poorly differentiated squamous cell carcinoma.