CODE: T29000 M90503

ID NOS: HX99445 146229

DIAGNOSIS: PLEURA – MALIGNANT MESOTHELIOMA

CLINICAL HISTORY: M/66. The patient was a non-smoker with no history of asbestos exposure. He had a 12 month history of increasing dyspnoea on exertion, and 2 months history of haemoptysis and right sided chest pain. A chest X-ray showed a large anterior mediastinal tumour which was resected.

MACROSCOPIC: The specimen consists of portion of tumour 100mm in maximum diameter, with a small portion of lung tissue attached. The cut surface shows firm creamy-brown tissue with areas of central necrosis.
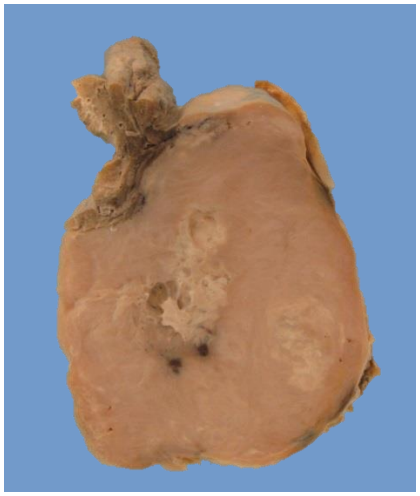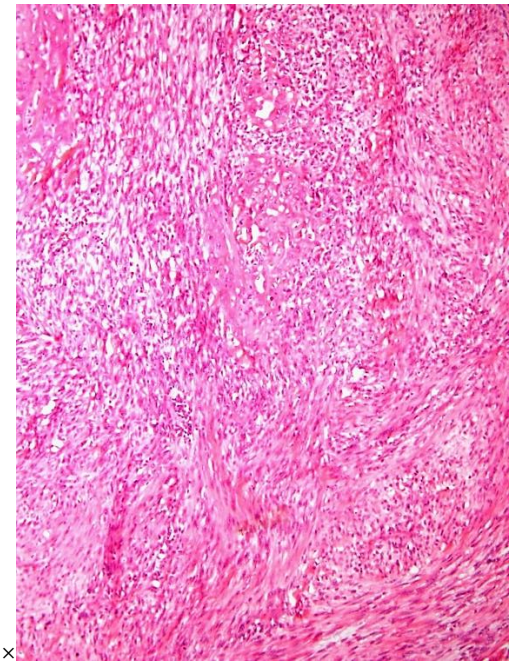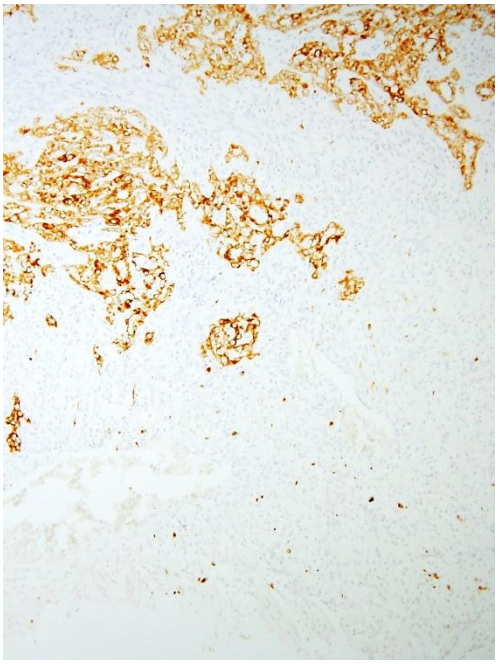
MICROSCOPIC: The mesothelioma has a biphasic pattern and consists predominantly of spindle shaped cells, with areas of plumper epithelial like cells at places showing gland formation. These are highlighted by a keratin stain (right image).