CODE: T2900 F9492/1

ID NOS: HX15586 57918

DIAGNOSIS: PLEURA – TUBERCULOUS EMPYEMA

CLINICAL HISTORY: M/59. The patient was diagnosed with pulmonary tuberculosis at the age of 31 years. This was treated with collapse therapy and health was apparently restored for 28 years. He then presented with cough, sputum, fever and loss of weight. The recurrence of tuberculosis was treated with drug therapy but a hydropneumothorax developed and later an empyema. It was thought that a bronchopulmonary fistula had developed and pneumonectomy was performed. The patient was said to be well 7 years later.

MACROSCOPIC: A number of caseous, partly calcified tuberculous foci are seen at the apex. The crescentic cavity on the left is the empyema lying between the thickened parietal and visceral pleura. There is a shaggy inflammatory exudate lining this space.

MICROSCOPIC: The pleura is thickened and fibrotic with scattered collections of inflammatory cells, and exudate on the surface (left image). A fibrocaseous nodule in the lung shows focal calcification and carbon pigmentation (right image).
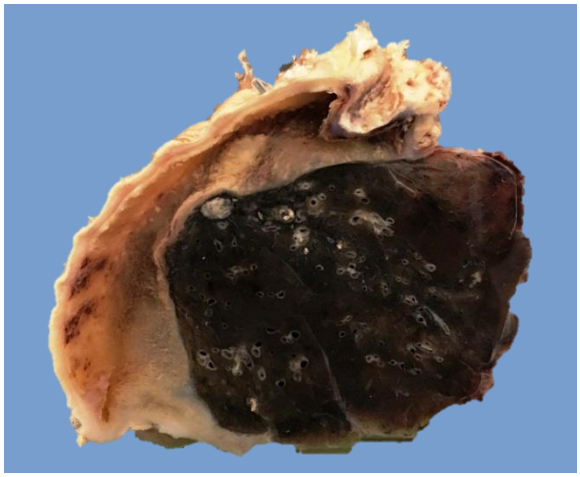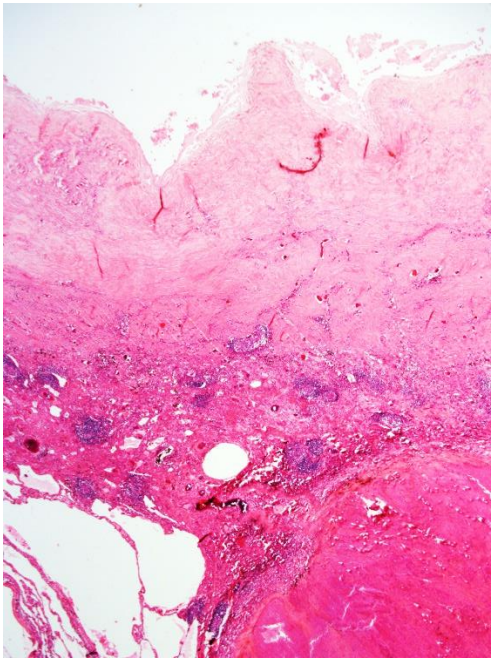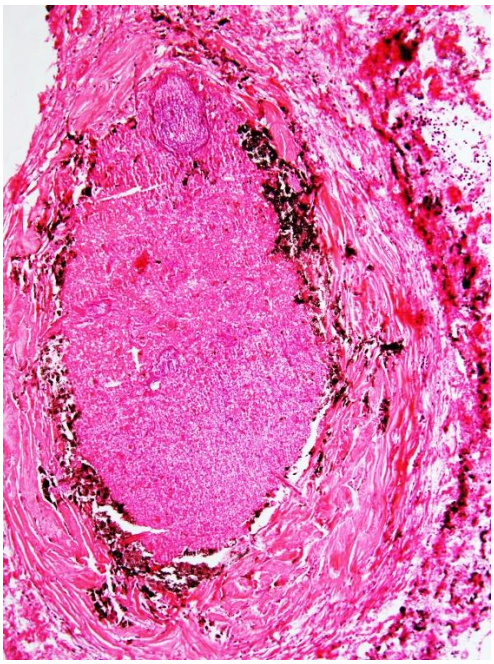
.