CODE: T2900 M9051/1

ID NOS: 47199

DIAGNOSIS: PLEURA – SOLITARY FIBROUS TUMOUR

CLINICAL HISTORY: M/65. The patient suffered from hypoglycaemic attacks. A chest Xray showed a large mass in the right lower lobe of the lung, and this was resected.

MACROSCOPIC: The specimen consists of portion of a firm tumour which originally measured 180mm in maximum diameter, with some attached lung tissue. The cut surface shows coarse lobules of pale tissue with scattered foci of calcification.

MICROSCOPIC: The tumour is encapsulated (left image) and consists mainly of spindle cells with numerous thin walled blood vessels (right image). Other parts of the tumour had more rounded or ovoid cells.
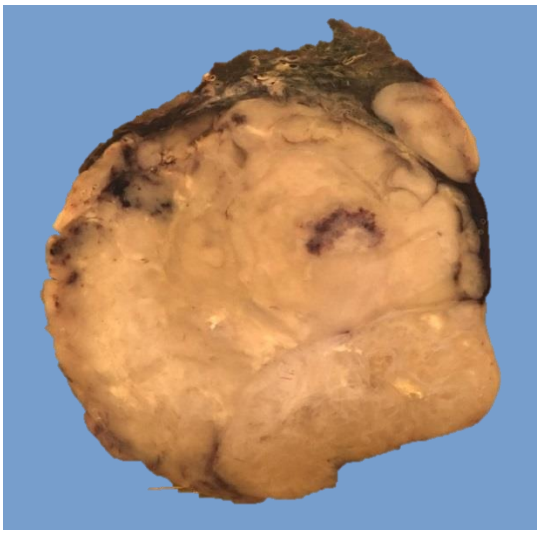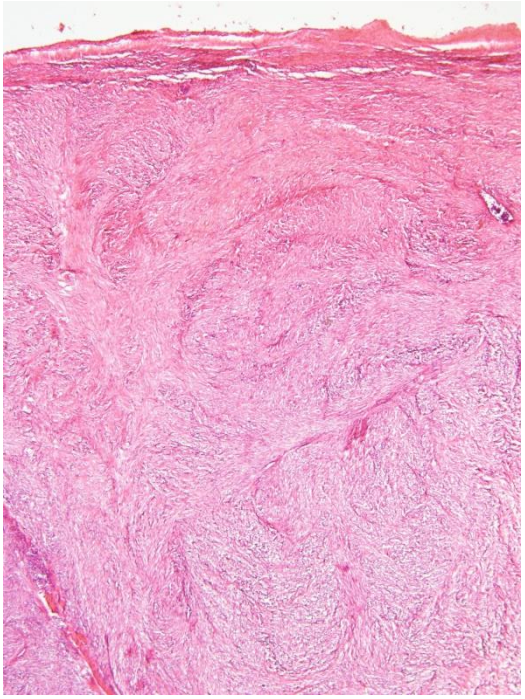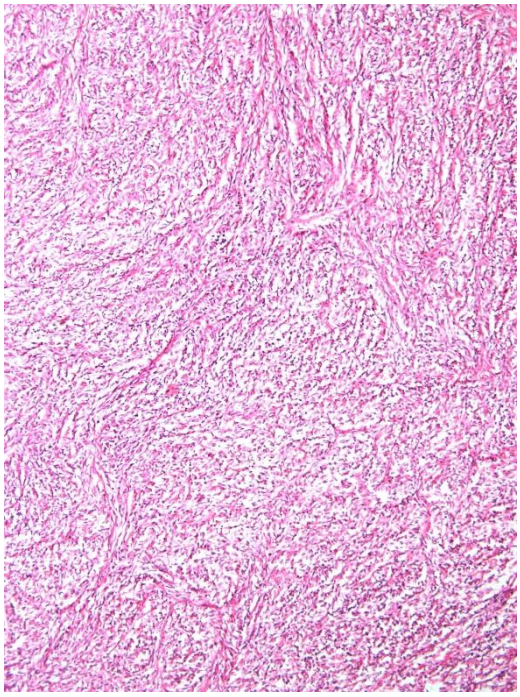
COMMENT: Hypoglycaemia is due to production of an insulin-like growth factor by the tumour.