CODE: T1100 F4503

ID NOS: H41642 A8124

DIAGNOSIS: RIB - SECONDARY HYPERPARATHYROIDISM.

CLINICAL HISTORY: M/72. Two years before death, this elderly man developed malignant hypertension and subsequently renal failure, eventually dying in uraemia. No record of relevant blood electrolyte level survives.

MACROSCOPIC: The rib was not fractured during life but was cut across to obtain tissue for histological examination. It is seen to be irregularly swollen and the cut ends show that the cortex in the main, is greatly thinned. On the reverse can be seen an oval hole where it has been completely resorbed. Many of the trabeculae have also disappeared. The renal failure was said to result from chronic pyelonephritis.
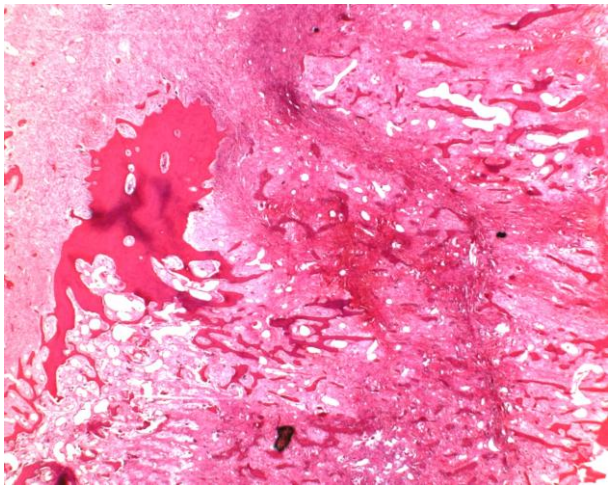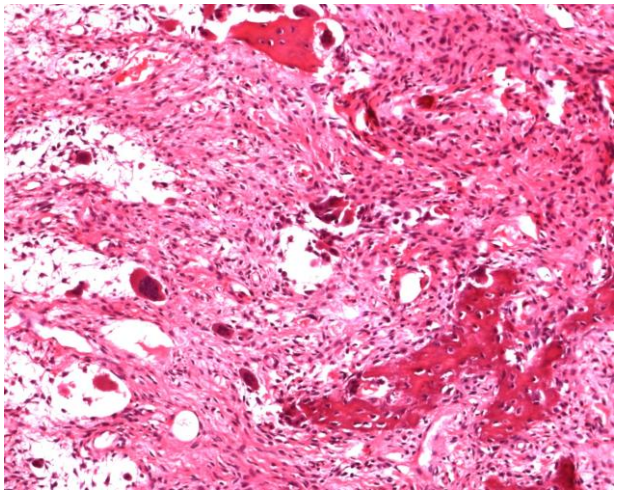
MICROSCOPIC: A good deal of the bone has been resorbed and replaced by loose connective tissue which envelope some osteoclasts. In some areas osteoid was developing.