CODE: T1100 M8803

ID NOS: H466765 178623

DIAGNOSIS: HUMERUS - PLEOMORPHIC SARCOMA

CLINICAL HISTORY: F/66. The patient complained of severe pain in the right upper arm. Investigations revealed a tumour of the humerus and a biopsy showed a sarcoma. A right forequarter amputation was performed.

MACROSCOPIC: The specimen consists of the lower half of the humerus. There is a tan coloured tumour 95mm in maximum dimension, which surrounds and has destroyed the bone. A medullary nail passes through the tumour.
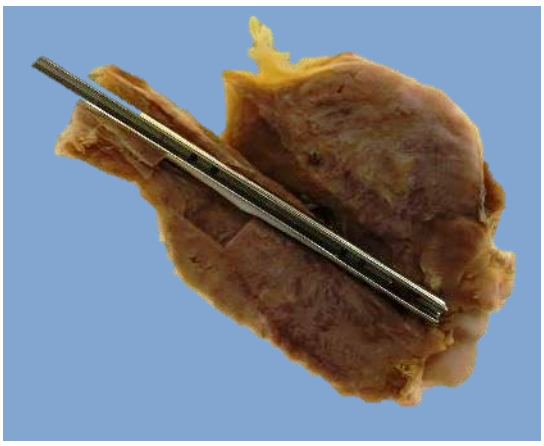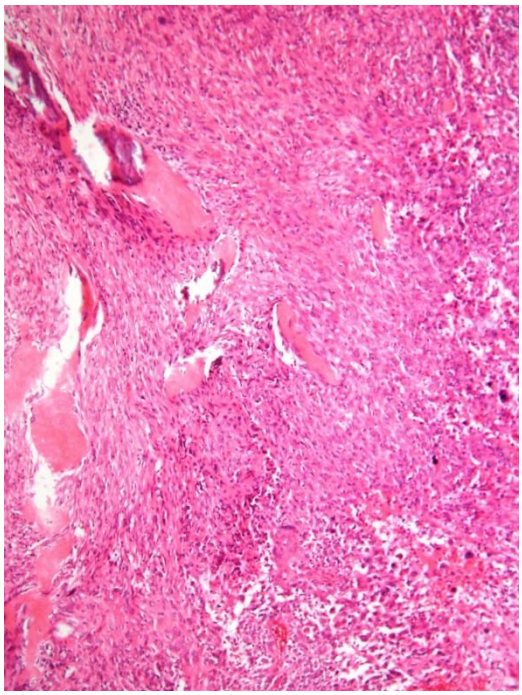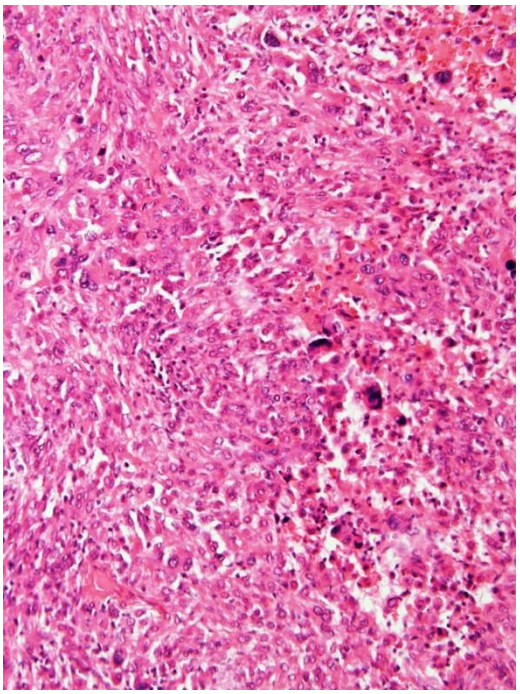
MICROSCOPIC: The tumour has destroyed the bone with some residual bony trabeculae present (left image). The tumour cells are round with eosinophilic cytoplasm. The nuclei are pleomorphic with mitoses and scattered tumour giant cells present (right image).