CODE: T1900 M8803

ID NOS: 124474

DIAGNOSIS: PLEOMORHIC SARCOMA OF SOFT TISSUE

CLINICAL HISTORY: M/Unknown age. Subutaneous mass of right thigh excised.

MACROSCOPIC: Specimen consists of skin, subcutaneous tissues and some underlying muscle. There is a tumour mass within the subcutaneous adipose tissue. The cut surface shows creamy, greyish and haemorrhagic areas.
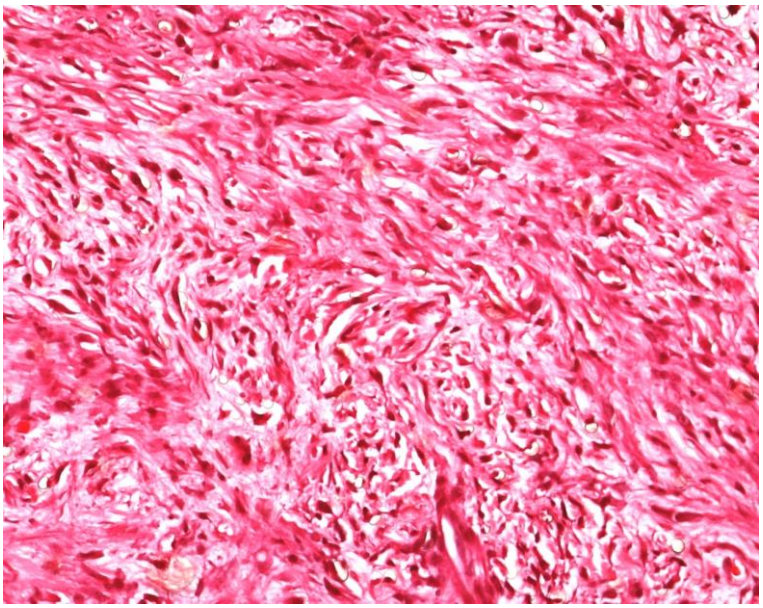
MICROSCOPIC: Sections showed a myxoid pleomorphic spindle cell sarcoma. Light microscopy and electron microscopy supported a diagnosis of pleomorphic sarcoma (Malignant fibrous histiocytoma).