CODE: T1900 M8830

ID NOS: 110894

DIAGNOSIS: FIBROUS HISTIOCYTOMA OF SOFT TISSUE.

CLINICAL HISTORY: M/38. Mass in soft tissues of subdeltoid area.

MACROSCOPIC: Specimen consists of portion of a pale yellow rounded mass.
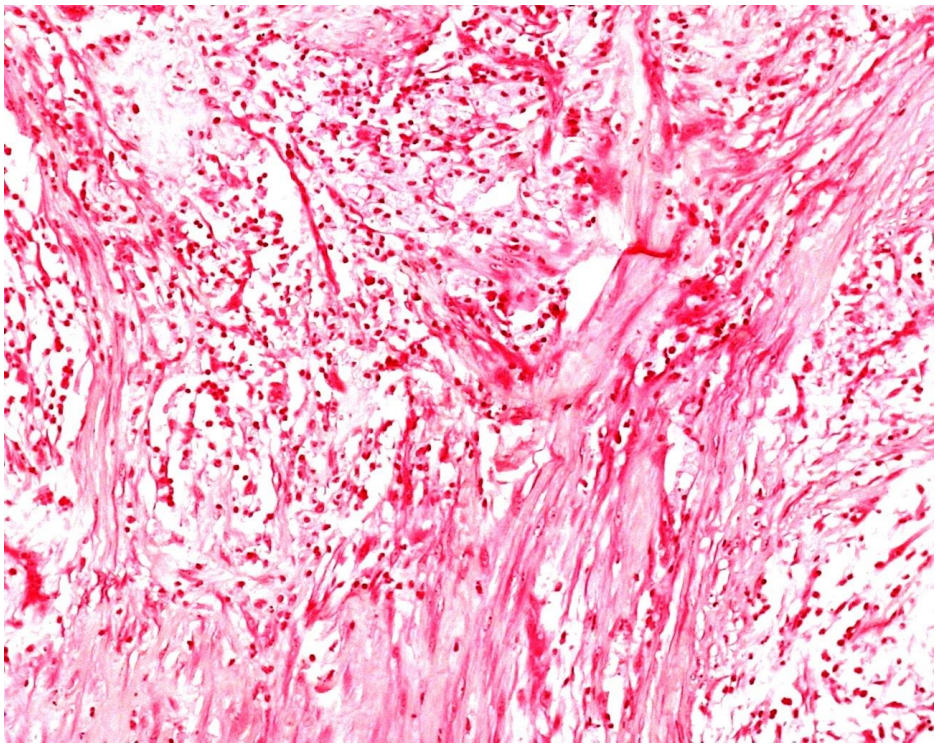
MICROSCOPIC: Sections show interlacing bundles of spindle shaped cells, some arranged in a whorled or "storiform" pattern. Inflammatory cells are also present.