CODE: T1900 M8853

ID NOS: 185059

DIAGNOSIS: SOFT TISSUE RETROPERITONEM - LIPOSARCOMA.

CLINICAL HISTORY: F/49. An asymptomatic mass in region of the left adrenal gland was removed.

MACROSCOPIC: The specimen consists of an ovoid pale yellow mass which measured 150x100x80mm and weighed 645g. The adrenal gland was stretched over the mass when received in the laboratory.
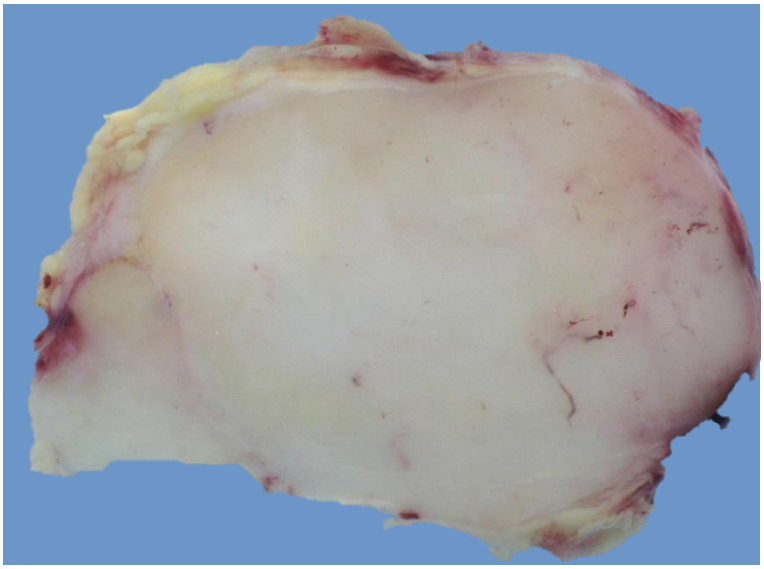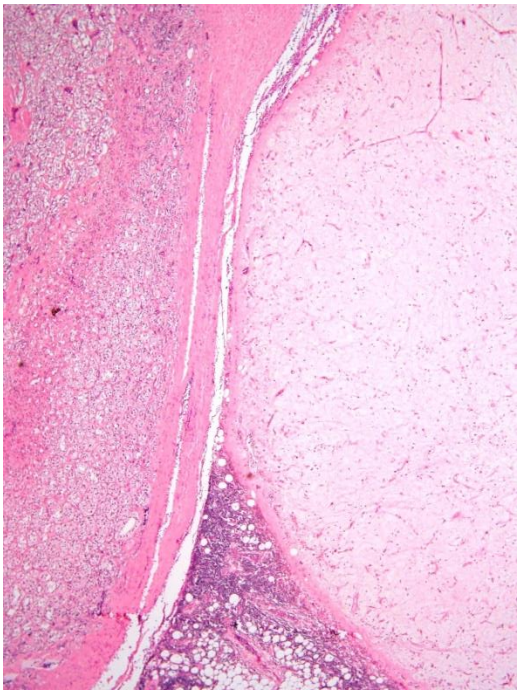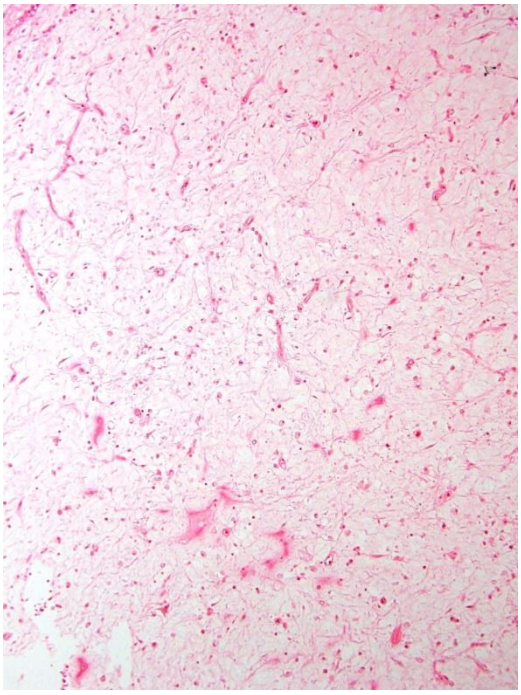
MICROSCOPIC: Sections show a low grade myxoid liposarcoma. The tumour is closely associated with the adrenal gland (left side of left image) but does not involve it. There is abundant myxoid stroma with a fine vascular pattern (right image)