**CODE:** T0100 M8821/1

**ID NOS:** H355180; 101381

**DIAGNOSIS:** SKIN OF ABDOMEN - DESMOID TUMOUR (FIBROMATOSIS).

**CLINICAL HISTORY:** F/16. Appendicectomy was performed four years before this admission to hospital, the latter being brought about because a lump developed in the region of the old operation scar. Biopsy of this lesion showed it to be a desmoid tumour and excision was performed. The old operation scar in which a keloid had also developed, was removed at the same time.

**MACROSCOPIC:** Cross section of normal rectus muscle is seen on the left, and the pale oval desmoid tumour on the right is attached to the internal aspect of the rectus sheath. A portion of the original scar is at top left and the pale ovoid structure immediately beneath the epidermis is a cross section of the keloid.
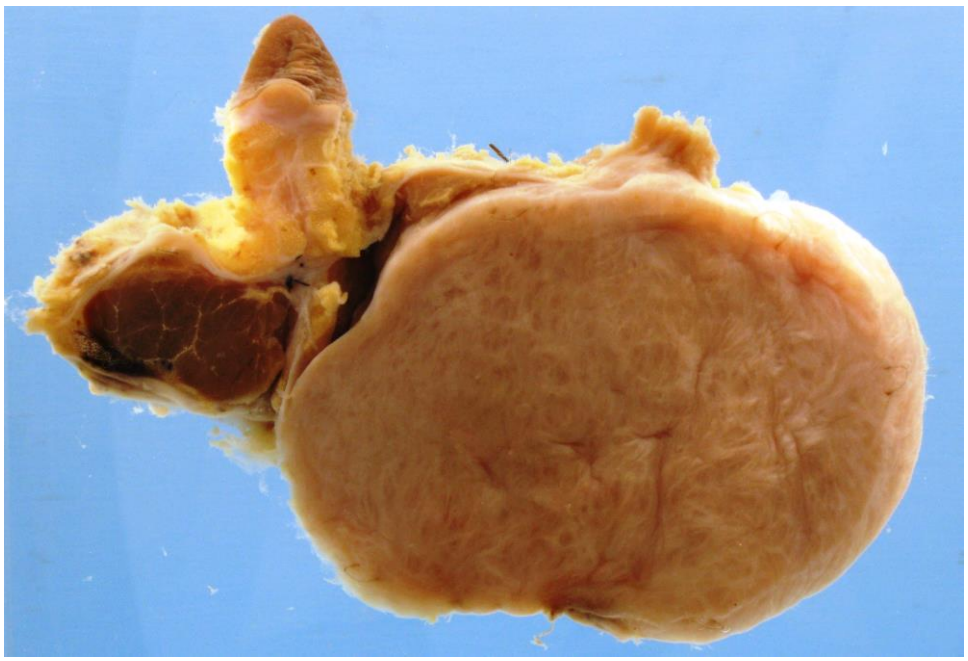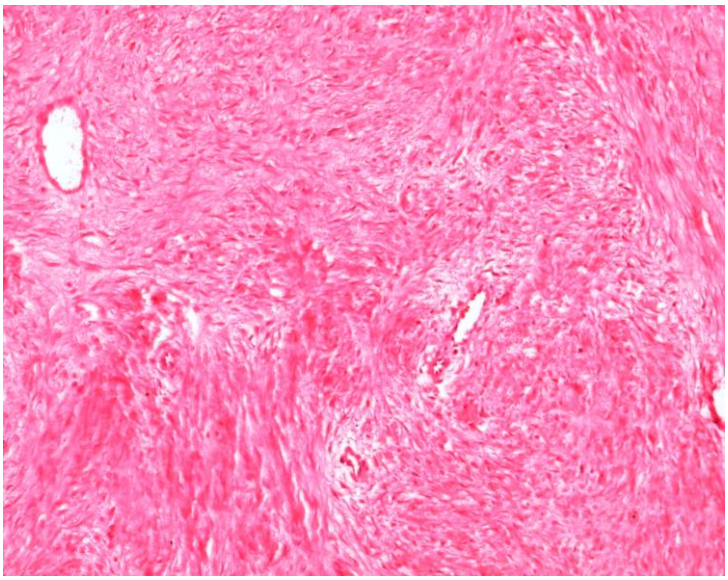
**MICROSCOPIC:** The tumour is made up of mature looking fibrocytes separated by collagen. Blood vessels are prominent.