CODE: T7100 M3441

ID NOS: H354824 99989

DIAGNOSIS: ARTERIOVENOUS ANEURYSM OF RENAL VESSELS

CLINICAL HISTORY: F/44. Mild pain in the left loin and some urinary frequency brought this patient to hospital. A loud 'machinery' murmur was present in the left renal region and an intravenous pyelogram showed a non-functioning kidney with a large vascular shadow at the hilum consistent with an arteriovenous fistula. Nephrectomy was performed.

MACROSCOPIC: The kidney is much smaller than normal, and in the hilum the cystic lesion is an aneurysm communicating with both the renal artery (red) and vein (blue).
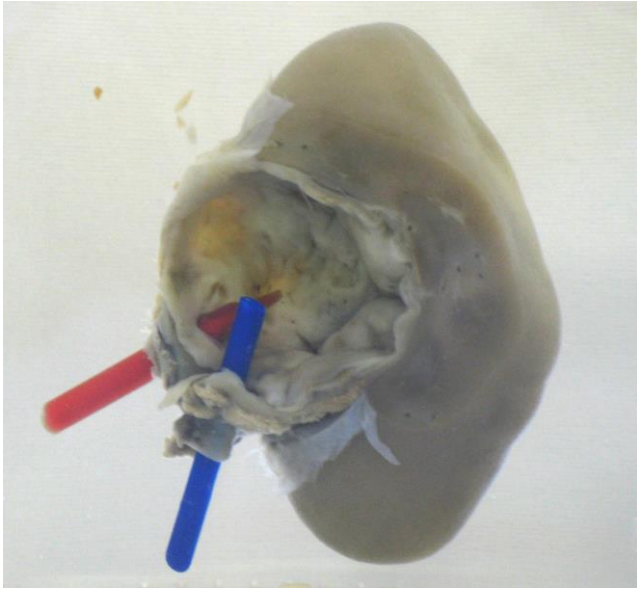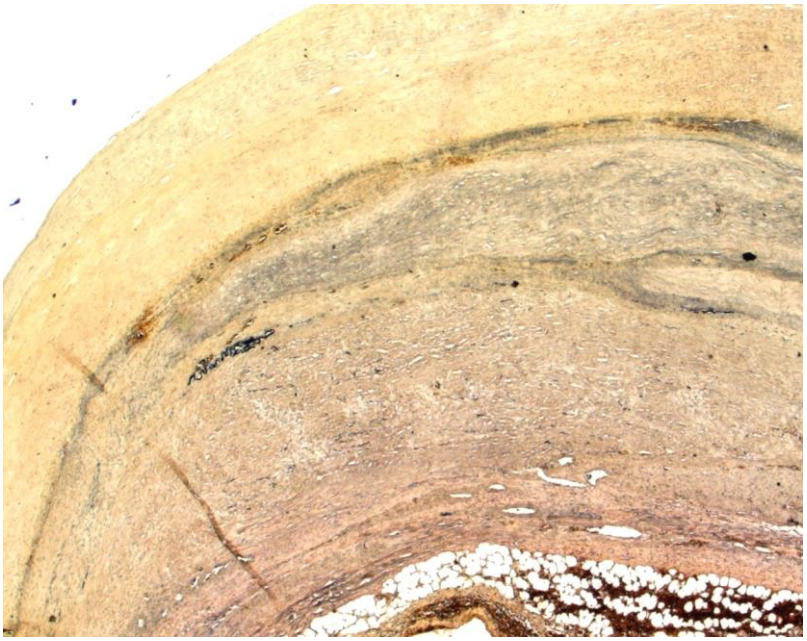
MICROSCOPIC: Remnants of an internal elastic lamina in the wall of the aneurysm show it to be of arterial origin which had subsequently ruptured into the vein (elastic stain).