CODE: T7100 M4402/2

ID NOS: 1180890 AB136332

DIAGNOSIS: KIDNEY - XANTHOGRANULOMATOUS PYELONEPHRITIS

CLINICAL HISTORY: F/62. The patient had a history of renal calculi. Two months earlier drainage of pus from a pyonephrosis of the right kidney was performed. Laparoscopic nephrectomy was commenced, but this was converted to on open operation because of inflammatory changes around the kidney.

MACROSCOPIC: The specimen consists of a slice of kidney showing replacement of the normal parenchyma by multiple irregular spaces lined by yellowish tissue. These spaces contained pus when received.
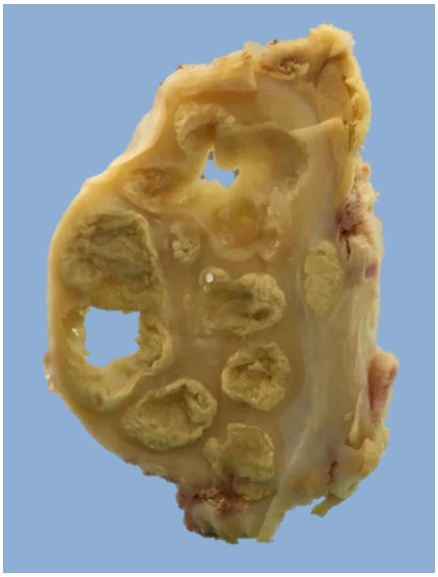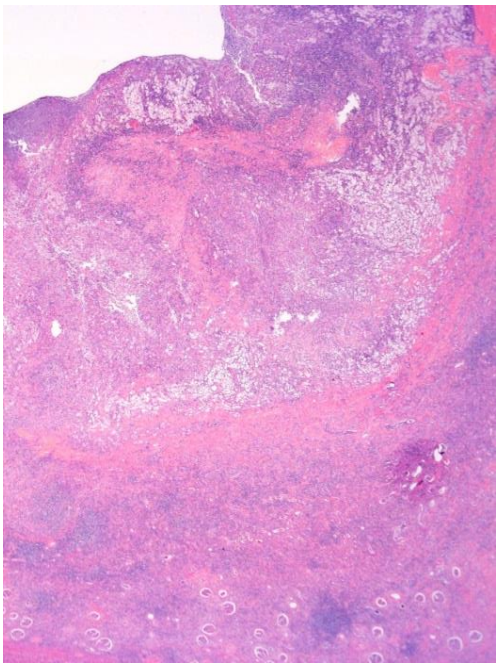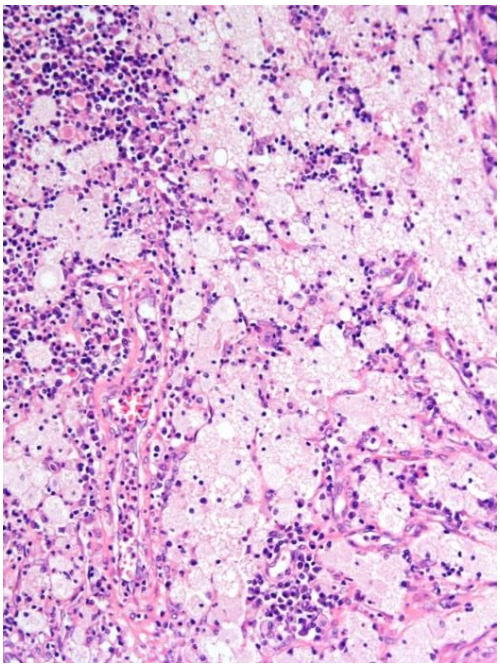
MICROSCOPIC: The left image shows part of a cystic space lined by granulation tissue in the top left corner. There are marked inflammatory changes with pale areas and areas of abscess formation. The renal cortical tissue at the bottom shows marked tubular atrophy and active chronic inflammation. The pale areas contain prominent foamy macrophages admixed with inflammatory cells (right image). The features are those of xantho-granulomatous pyelonephritis.