CODE: T7100 M8313/5

ID NOS: 8629

DIAGNOSIS: KIDNEY - CLEAR CELL RENAL CELL CARCINOMA.

CLINICAL HISTORY: M/60. No history available.

MACROSCOPIC: The lower half of the kidney is mostly replaced by a lobulated variegated tumour. This has extended into and distended the renal pelvis and has involved the contiguous portion of the ureter. This is an unusual method of spread of renal cell carcinoma.
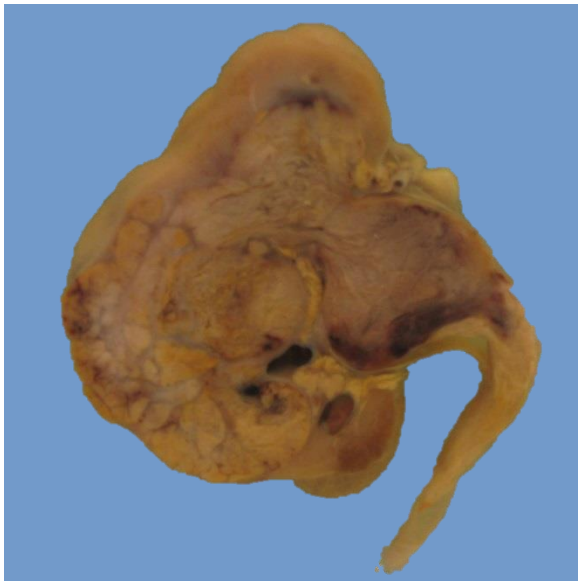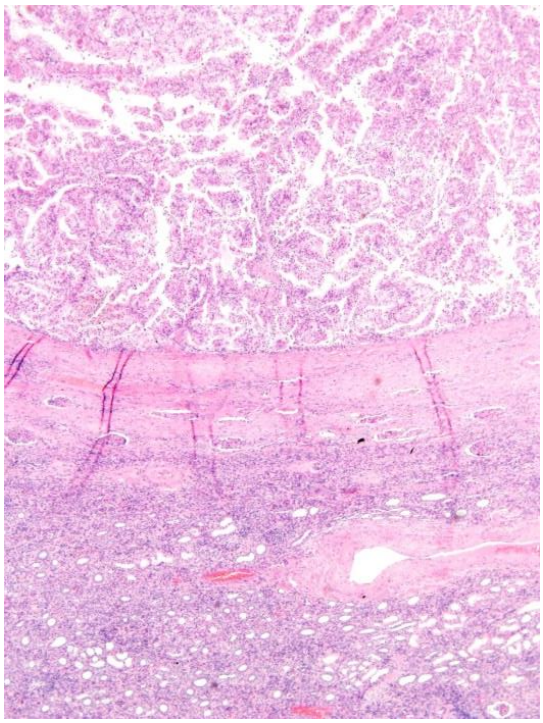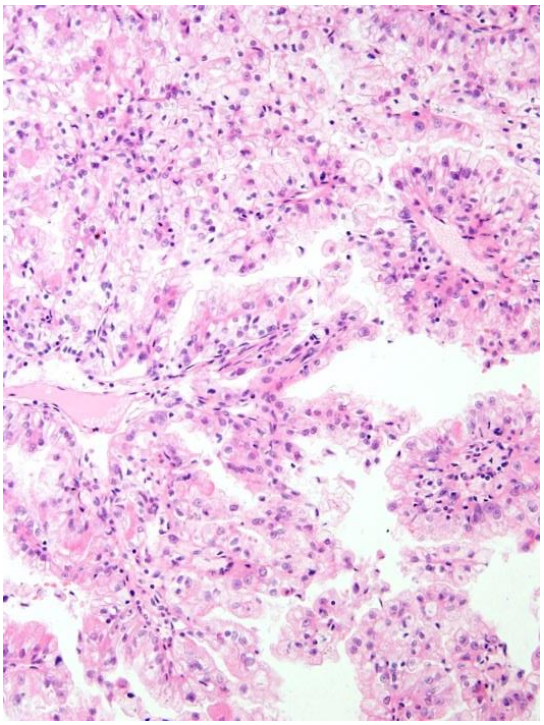
MICROSCOPIC: A fibrous capsule separates this clear cell renal carcinoma from surrounding renal tissue, which shows atrophic changes (left image). The tumour forms papillary and glandular structures and the tumour cells have abundant clear cytoplasm (right image).