CODE: T71020 M82900

ID NOS: H450050 162353

DIAGNOSIS: ONCOCYTOMA OF KIDNEY.

CLINICAL HISTORY: F/69. The patient presented with 20 hour history of right sided abdominal pain radiating to the right groin. Investigations showed urinary tract infection with no evidence of obstruction. CT and ultrasound showed a solid mass in the left kidney and nephrectomy was performed.

MACROSCOPIC: Specimen consists of portion of the left kidney in which there is a well circumscribed tumour 70mm in maximum extent, attached to the medial side of the kidney. The cut surface of the tumour brown tissue (colour has faded) with irregular foci of haemorrhage.
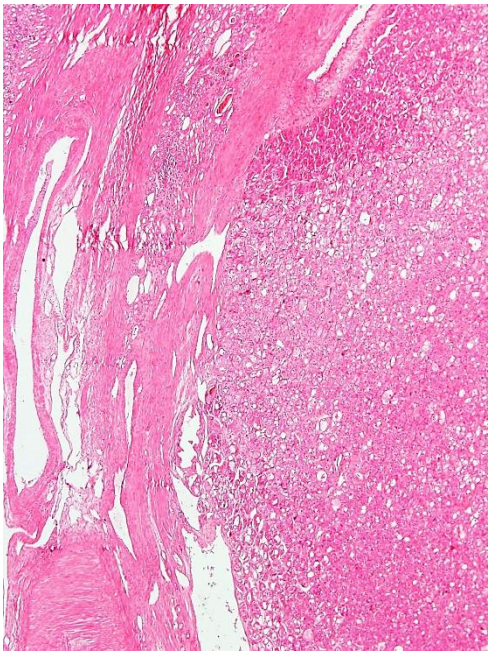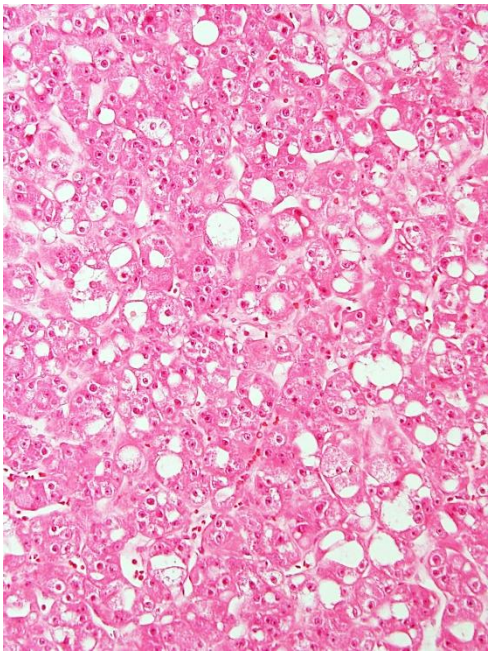
MICROSCOPIC: The sections show large, uniform cells with abundant eosinophilic granular cytoplasm, consistent with an oncocytoma.